

# Tumoren des hinteren Augenabschnitts

Herkunftsgewebe

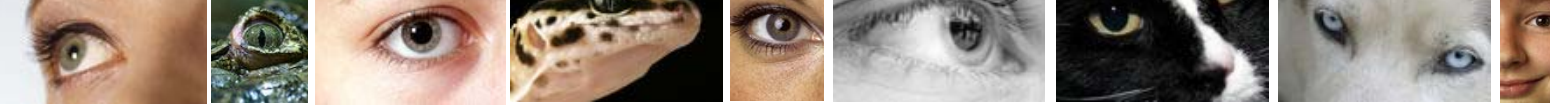
Netzhaut

Aderhaut

Dignität

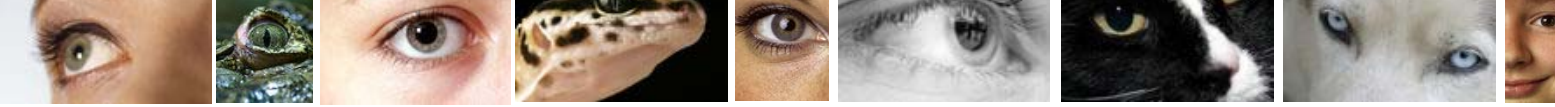
benigne

maligne

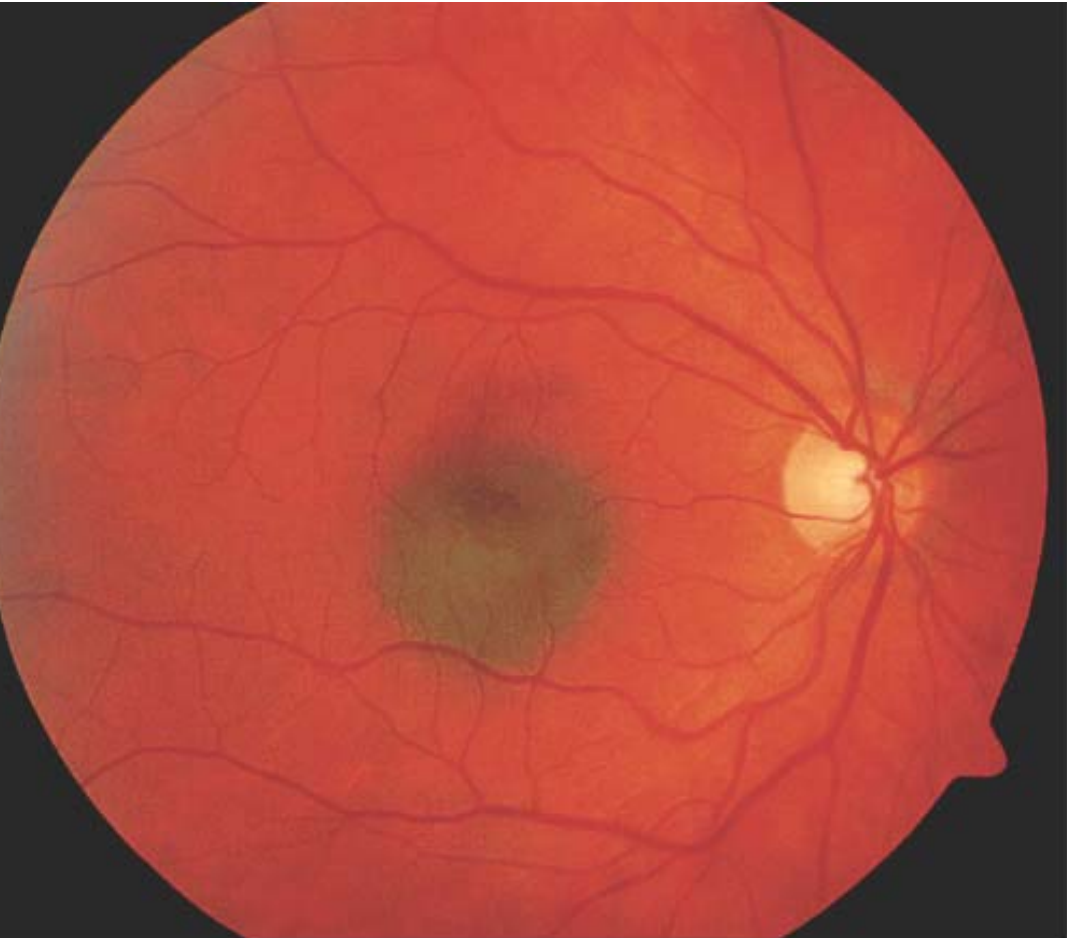

## Symptome

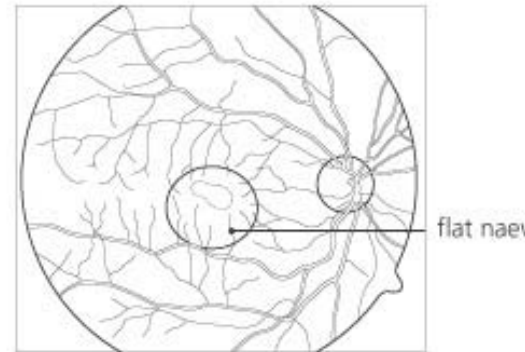
- Keine (90 %)
- Sehverschlechterung (manchmal)
- Schmerzen (extrem selten)
- Schielen (selten)
- Größenänderungen des Auges (selten)
- Farbänderungen des Auges (selten)

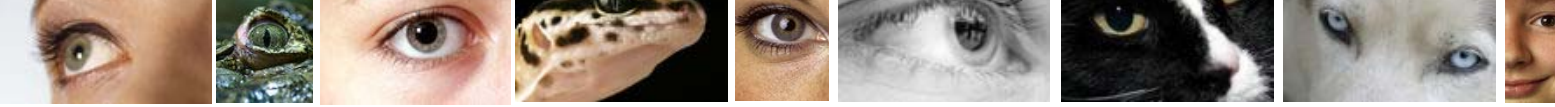


# Aderhautnävus

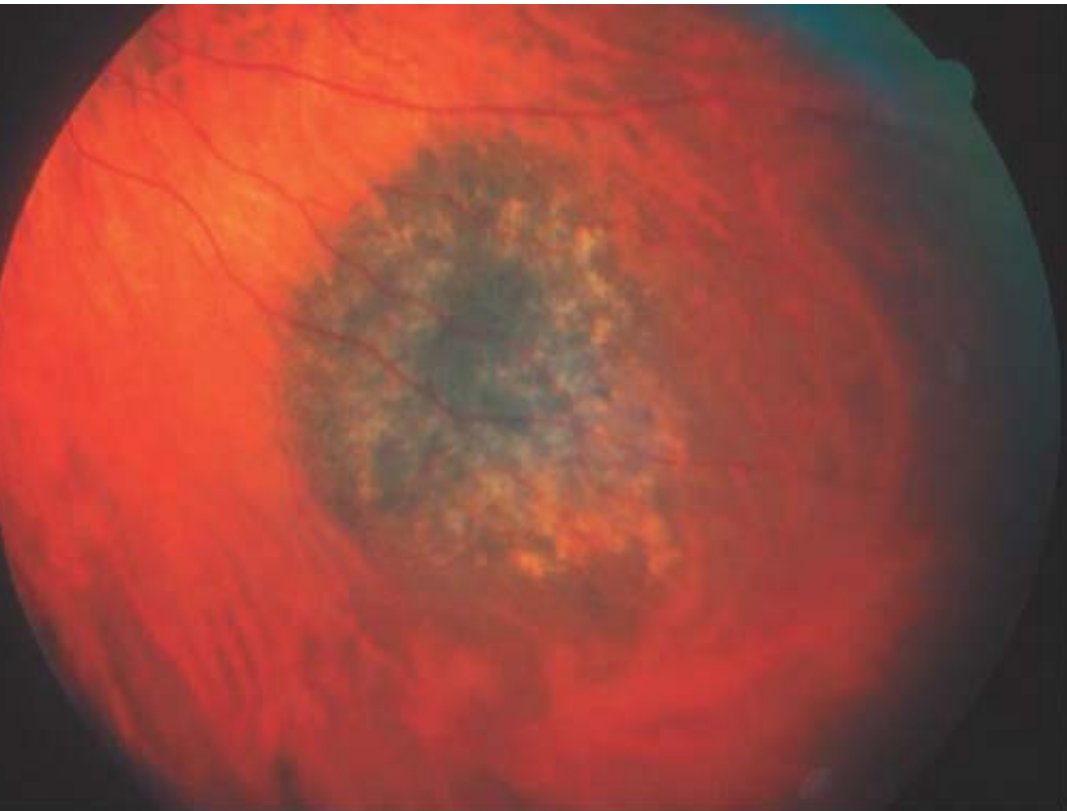


ca. 10 % aller Augen  
Risiko für maligne Entartung  
1/50.000 in 10 Jahren

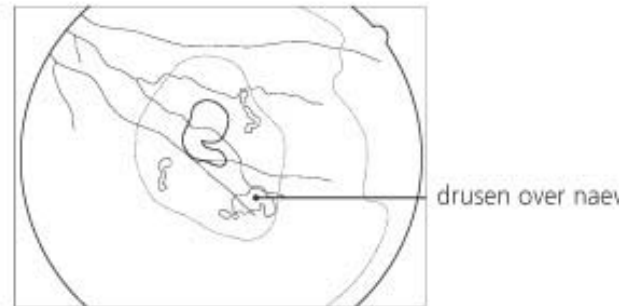


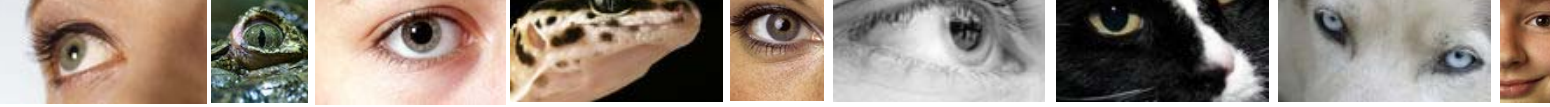


# Aderhautnävus

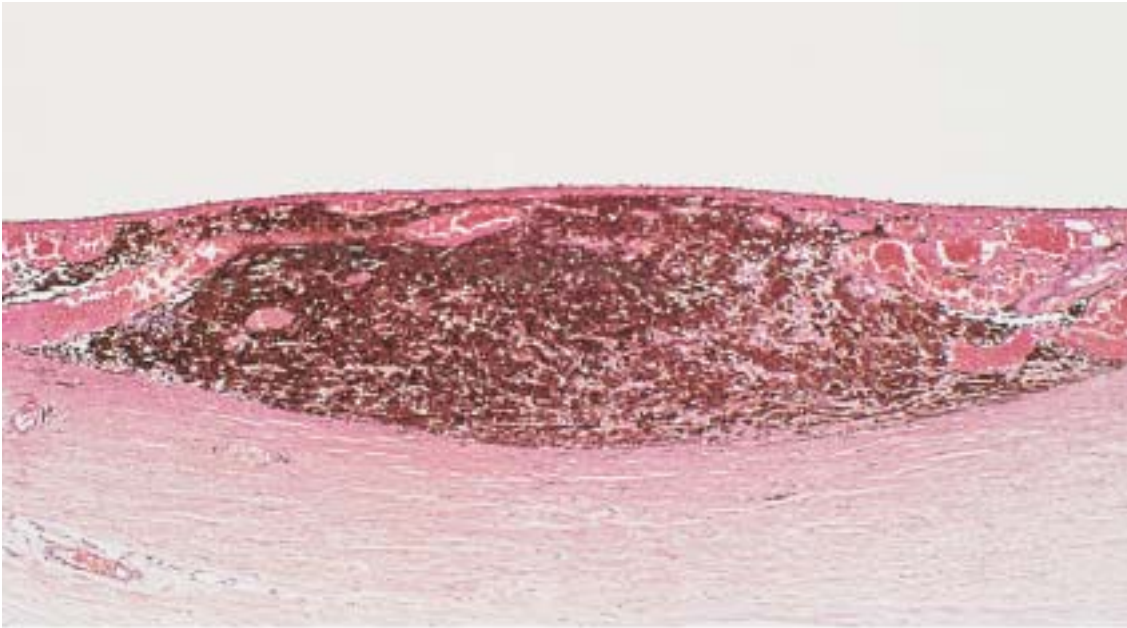


**Therapie:**  
Kontrolle  
Fotodokumentation  
Cave: Größenwachstum



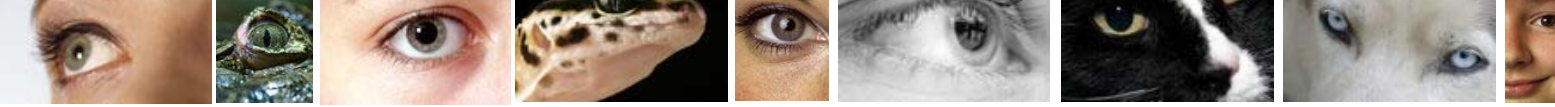


## ***Aderhautnävus: Histopathologie***

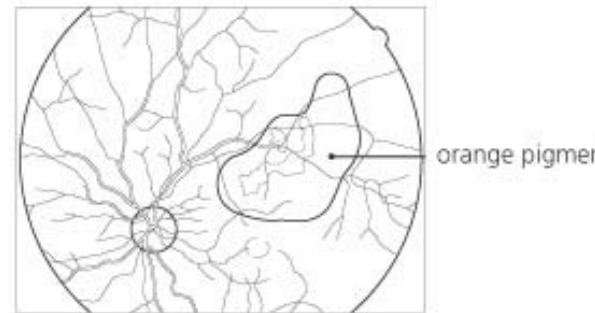
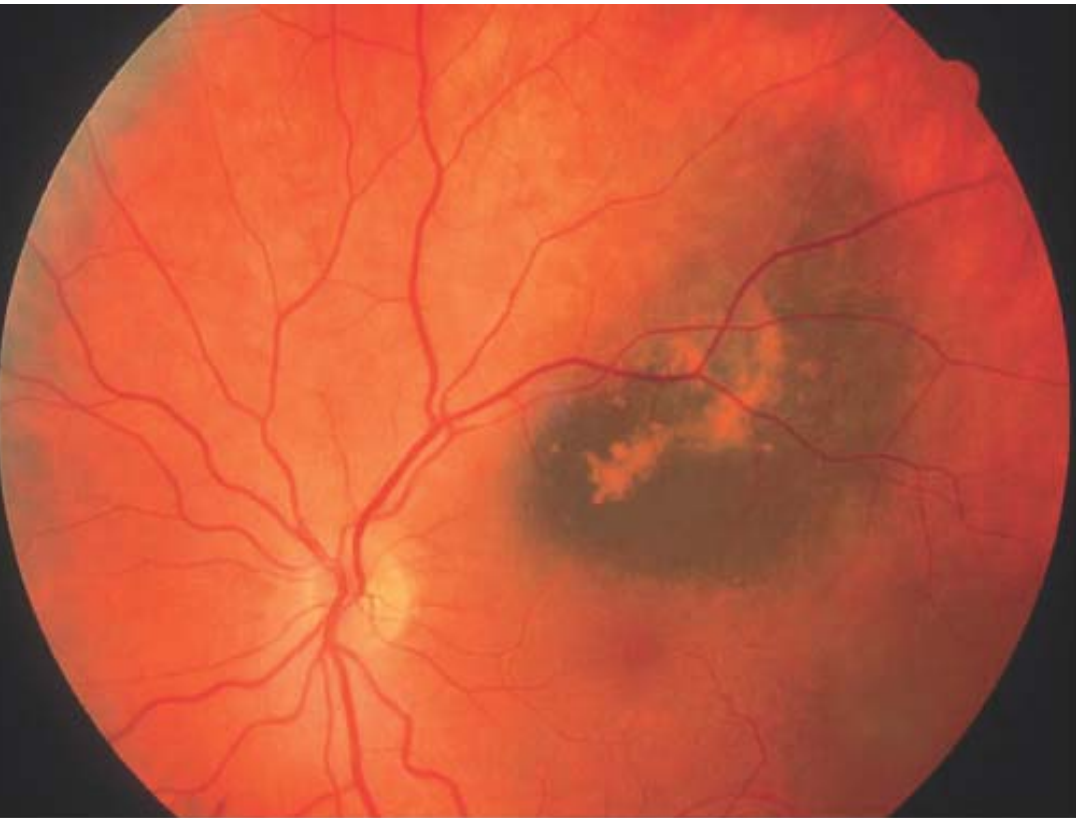


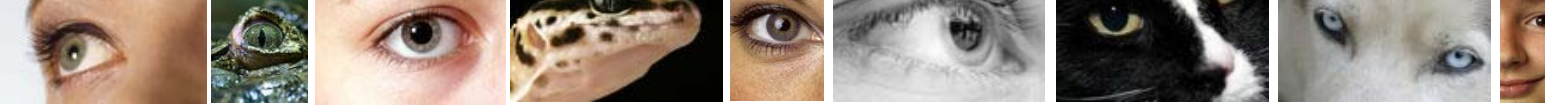
© 2005 Elsevier Ltd. Spalton et al: Atlas of Clinical Ophthalmology 3e





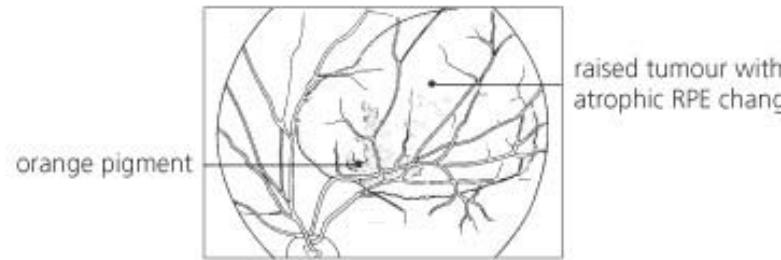
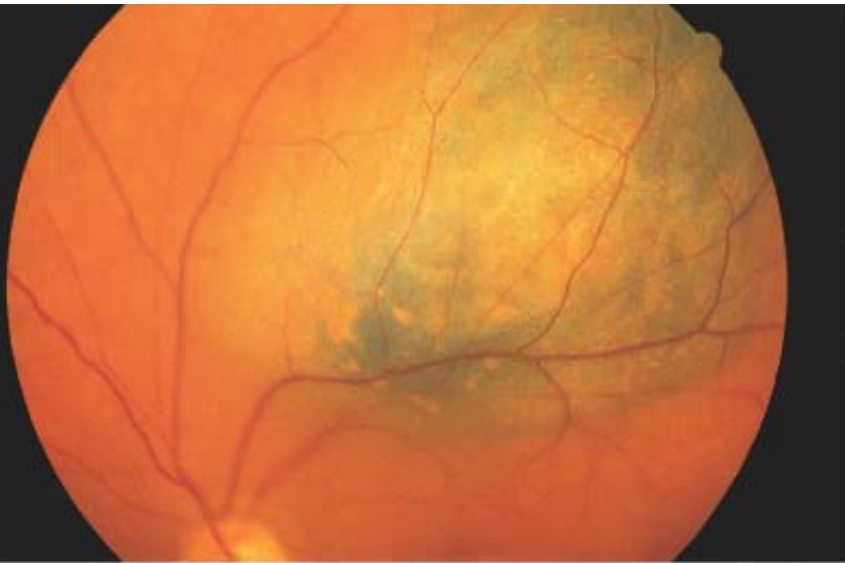## ***Aderhautnävus: „orange pigment“***

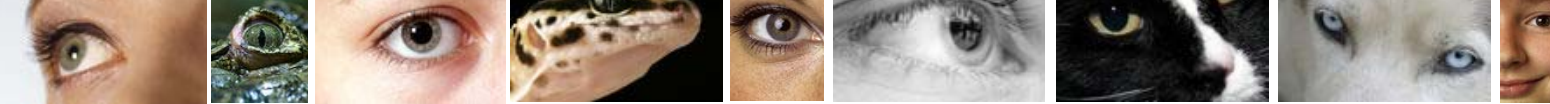




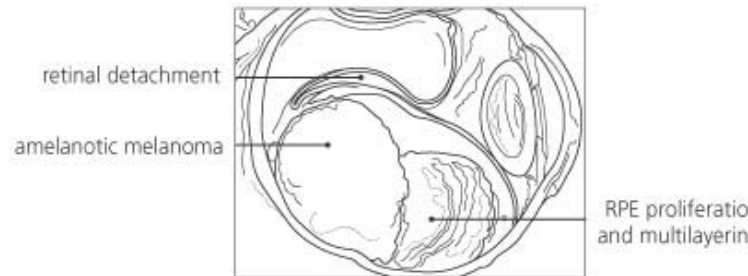
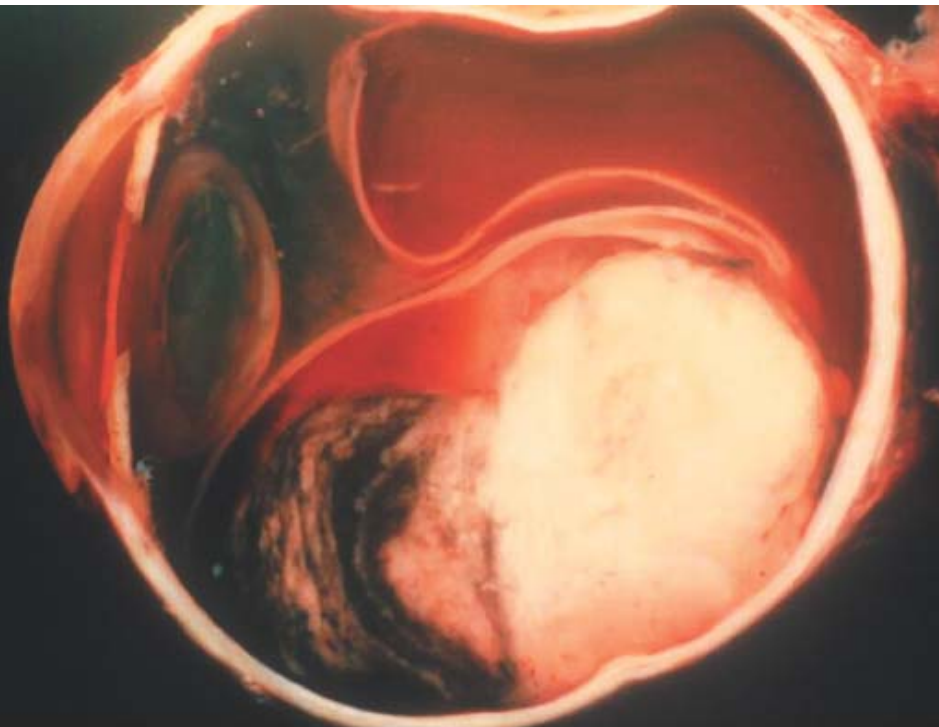
# ***Aderhautnävus oder Aderhautmelanom ?***

## ***Prominenz ? Wachstum ?***



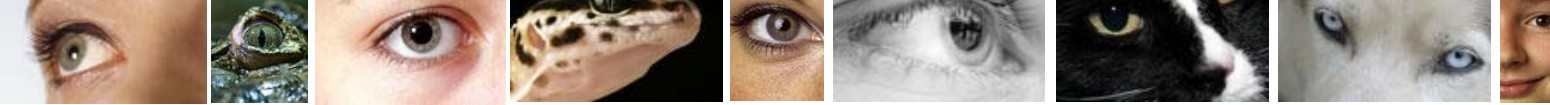


## ***Aderhautmelanom: amelanotisch Begleitamotio, RPE Proliferation***



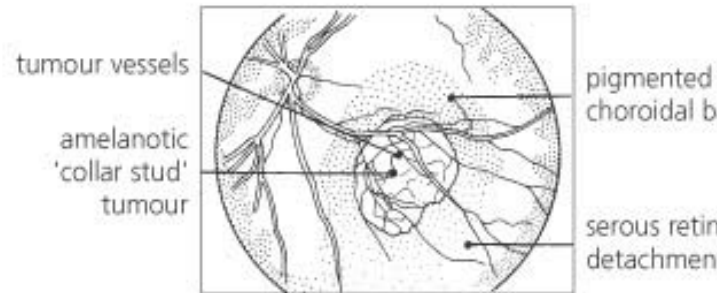
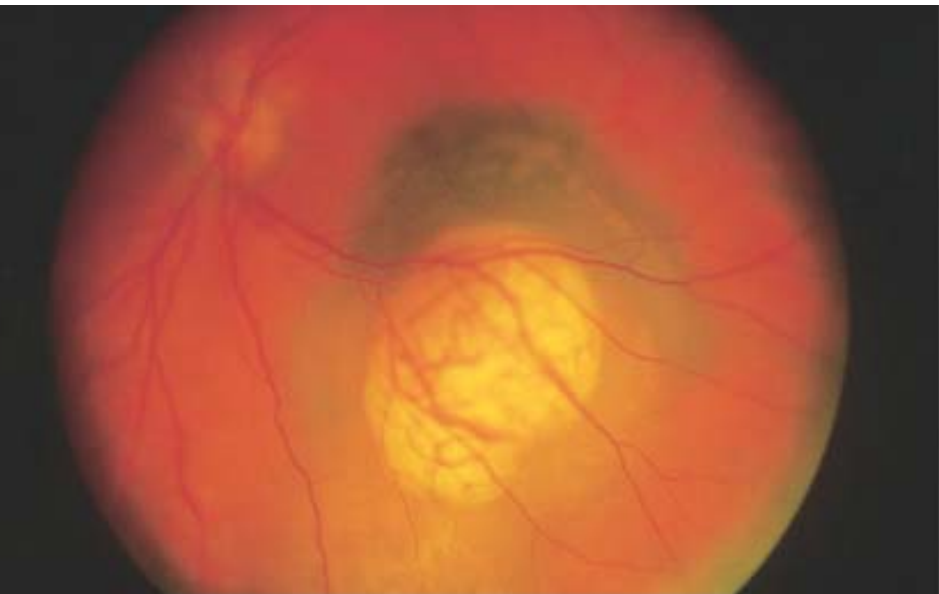**Inzidenz: 0.8 / 10.000 / Jahr**  
**5 Jahresüberlebensrate: 75 %**  
**Metastasen: Leber, Lunge**

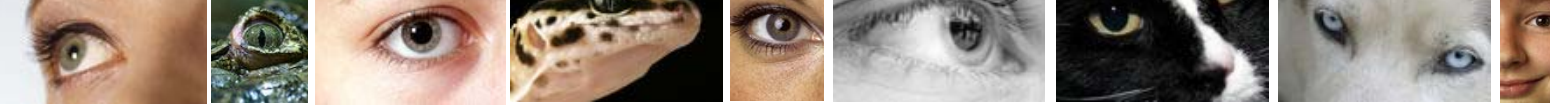




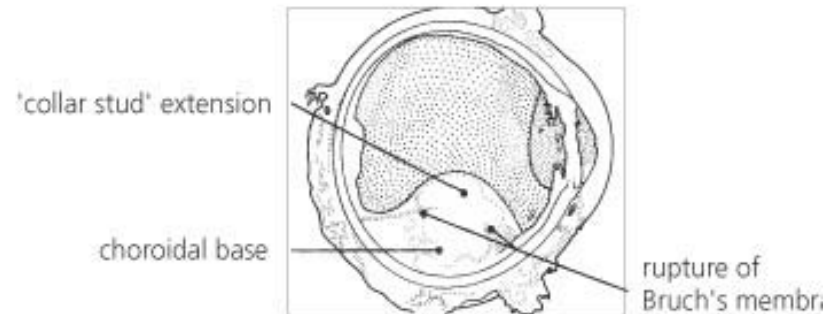
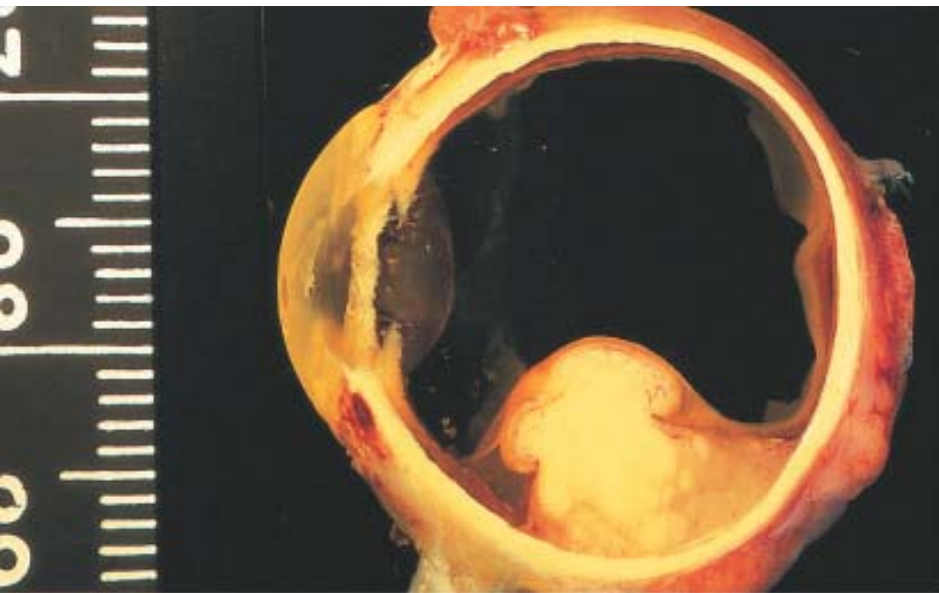# Aderhautmelanom

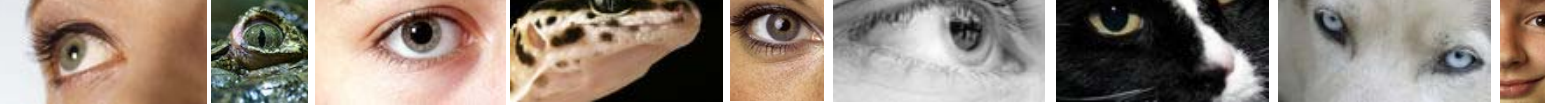
**Ätiologische Faktoren:**  
Nävus, okuläre Melanose  
Dysplastisches Nävussyndrom  
Neurofibromatose  
Chromosemanomalien



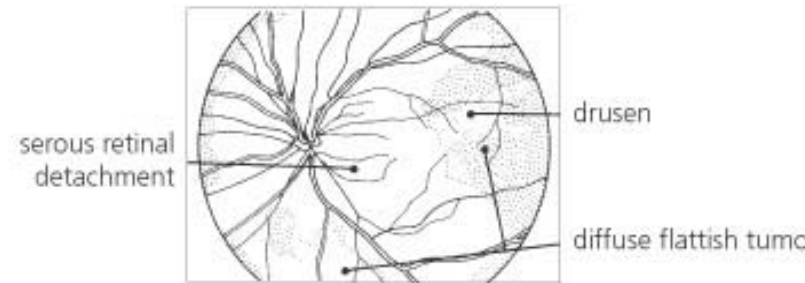
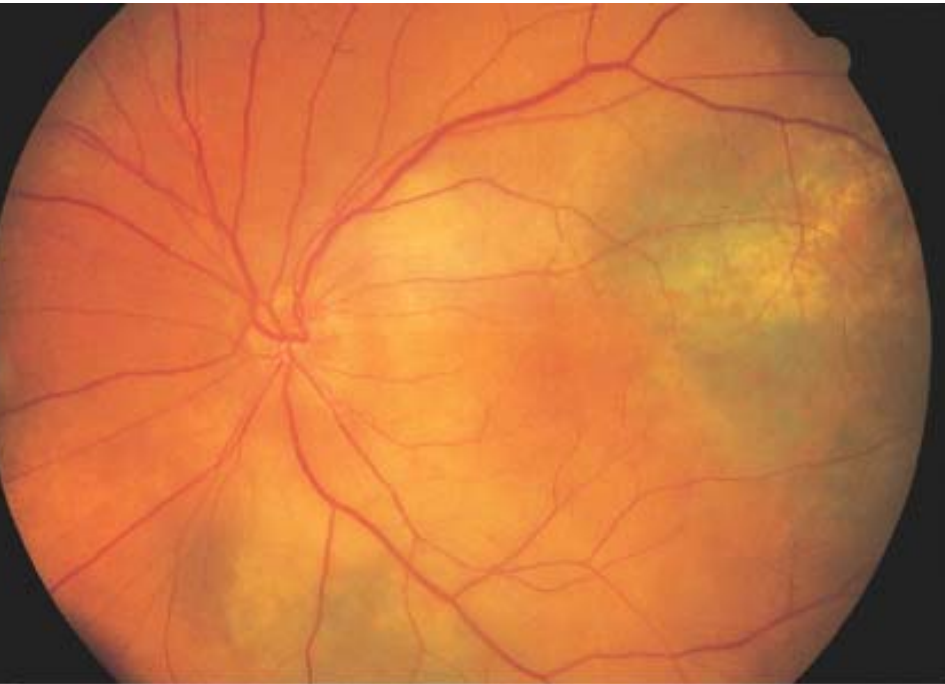


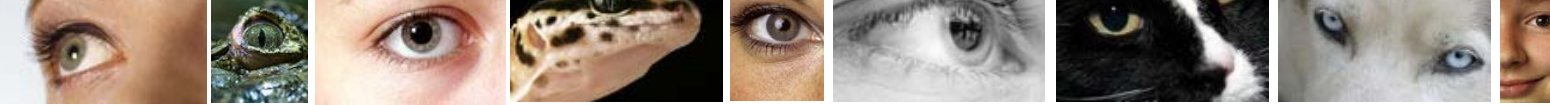
## **Champignonkonfiguration nach Durchbrechen der Bruchschen Membran**



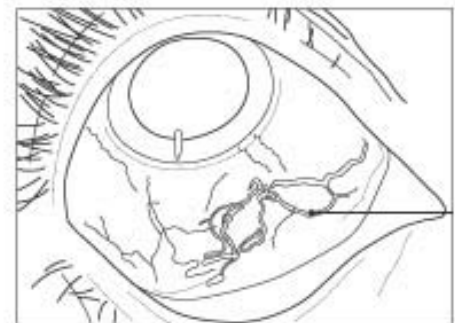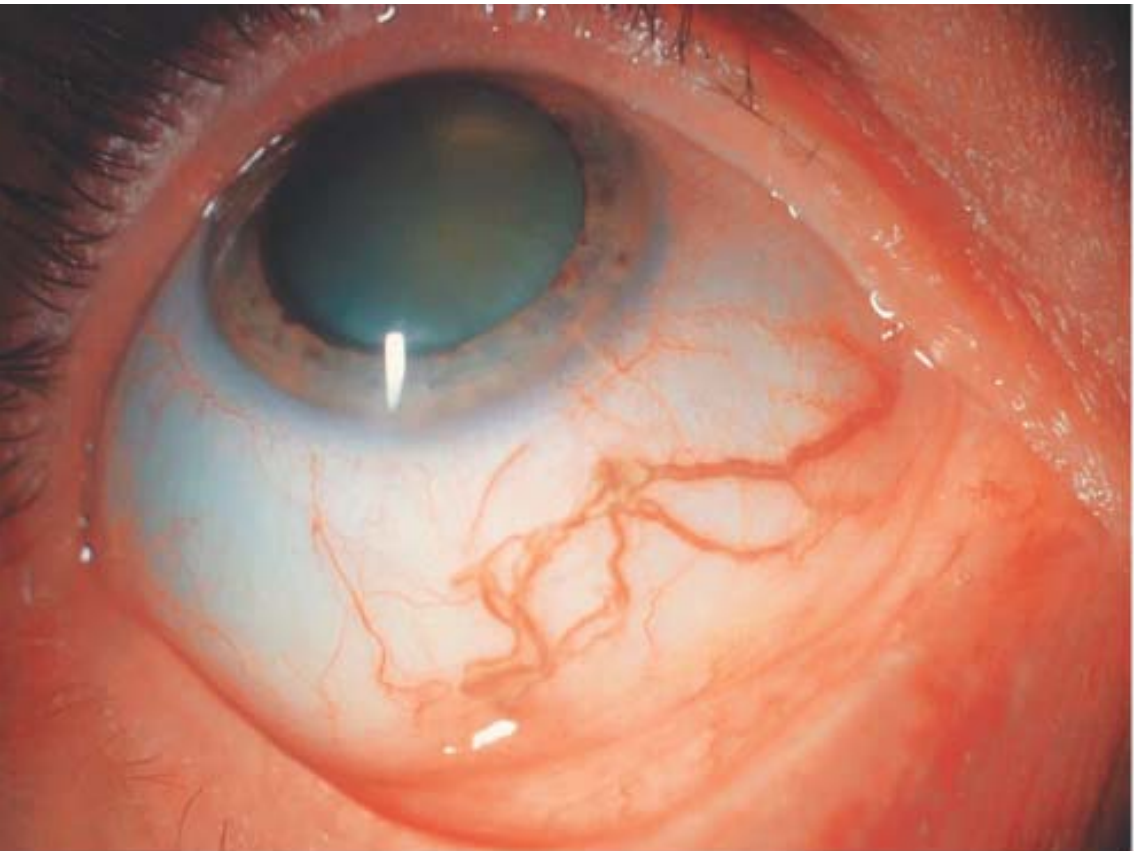


# ***Seröse Netzhautablösung als Begleitzeichen beim Aderhautmelanom***



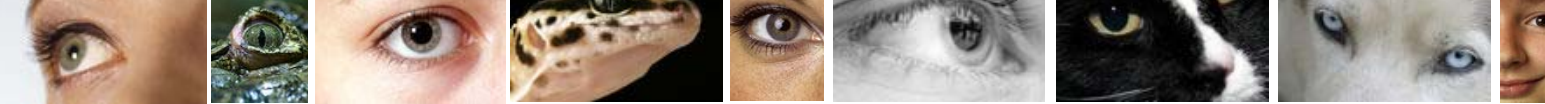


## ***Dilatierte episklerale Gefäße als Begleitzeichen beim Aderhautmelanom***

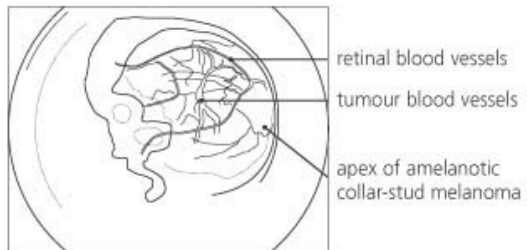
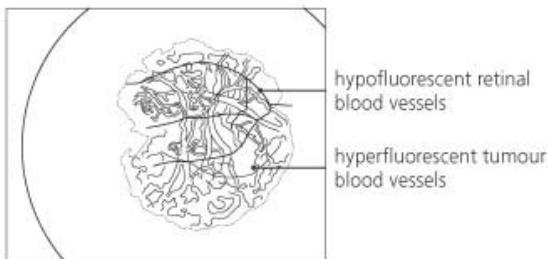
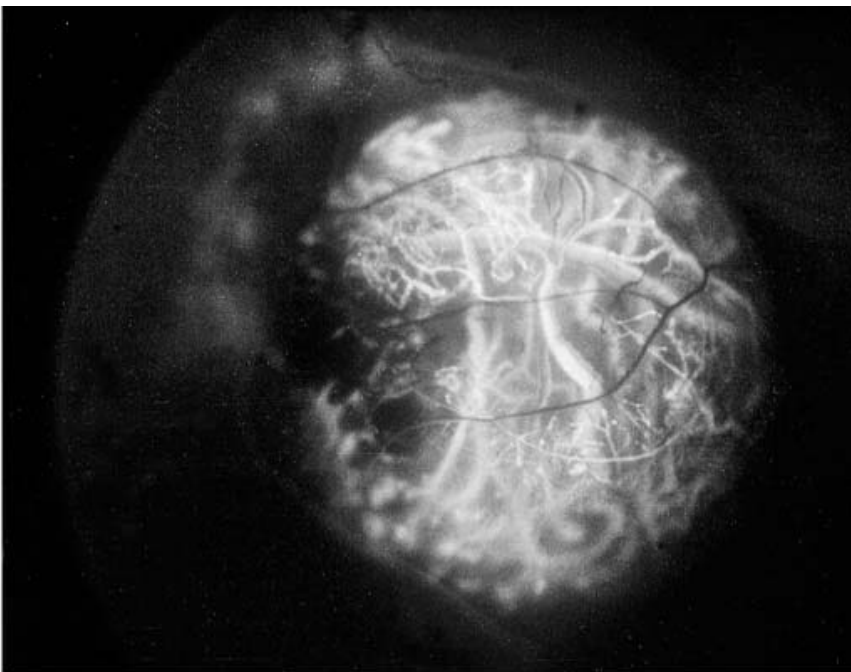
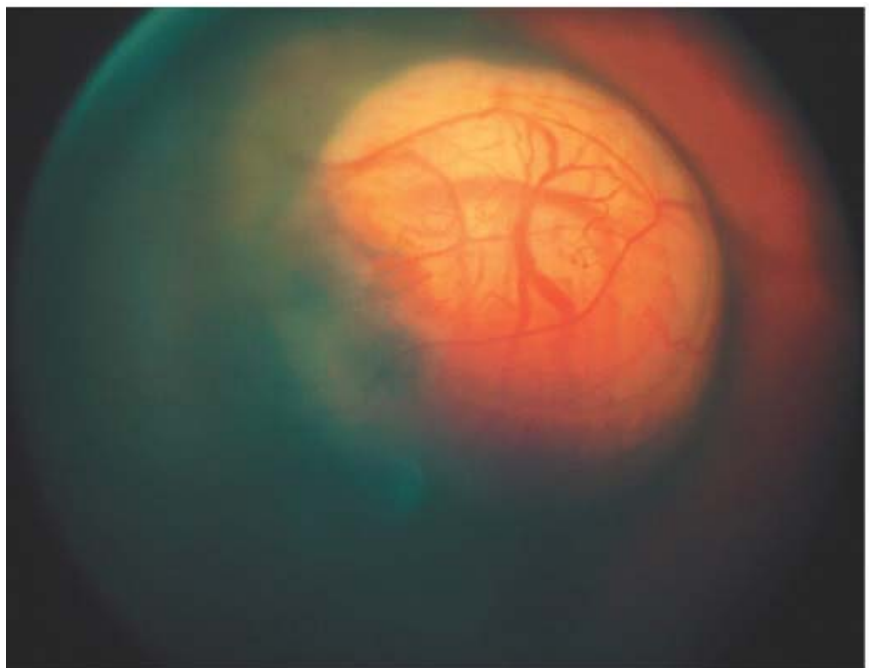


dilated ves

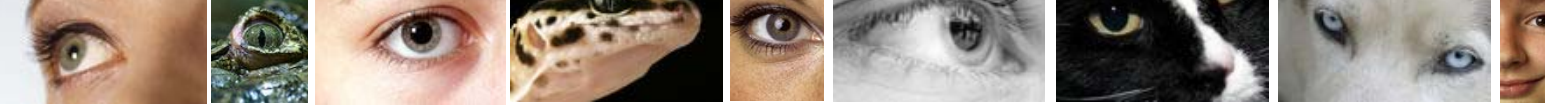




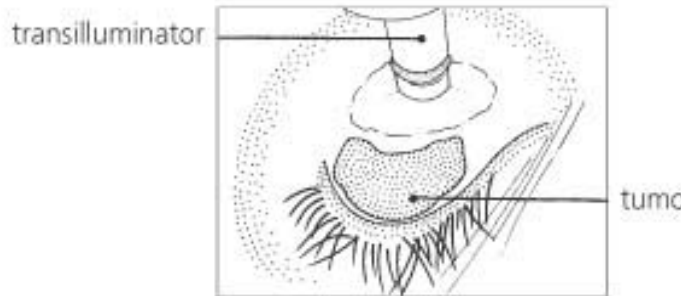

# ***Tumoreigene Gefäße beim Aderhautmelanom***

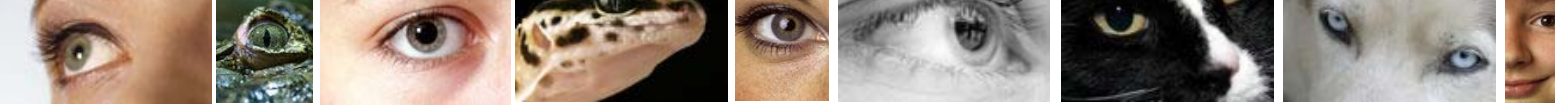




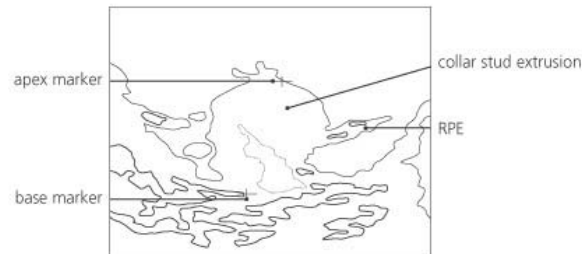
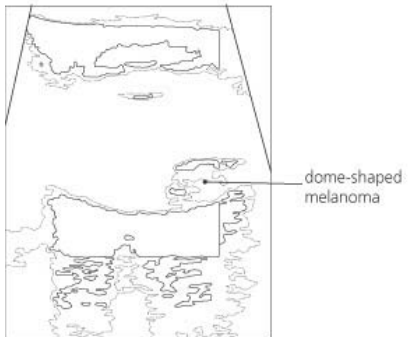


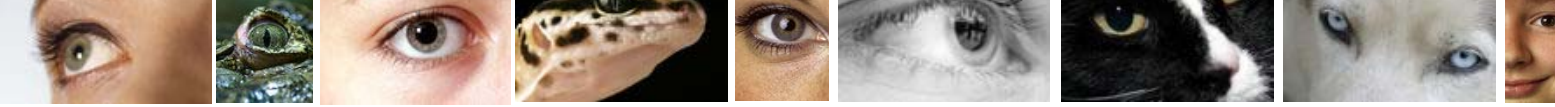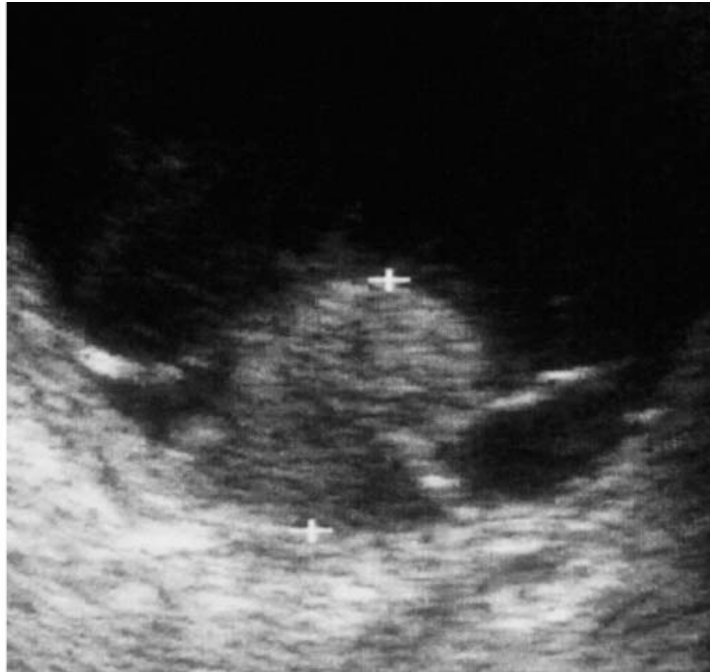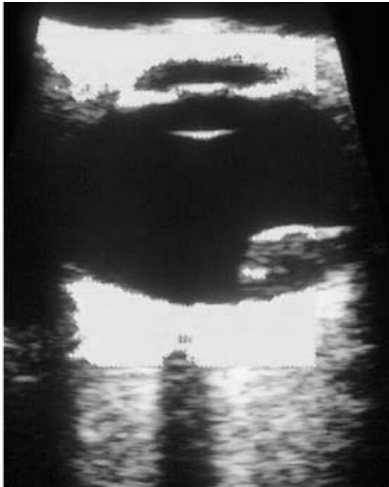
## **Diagnostik: Diaphanoskopie**



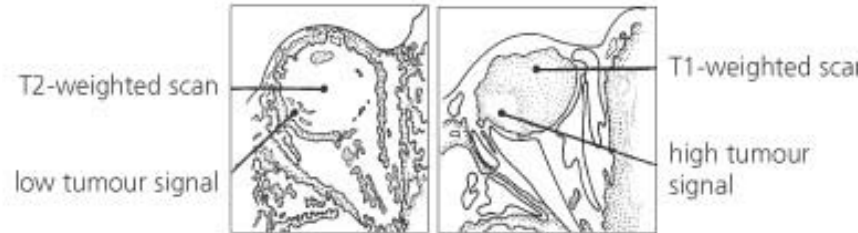
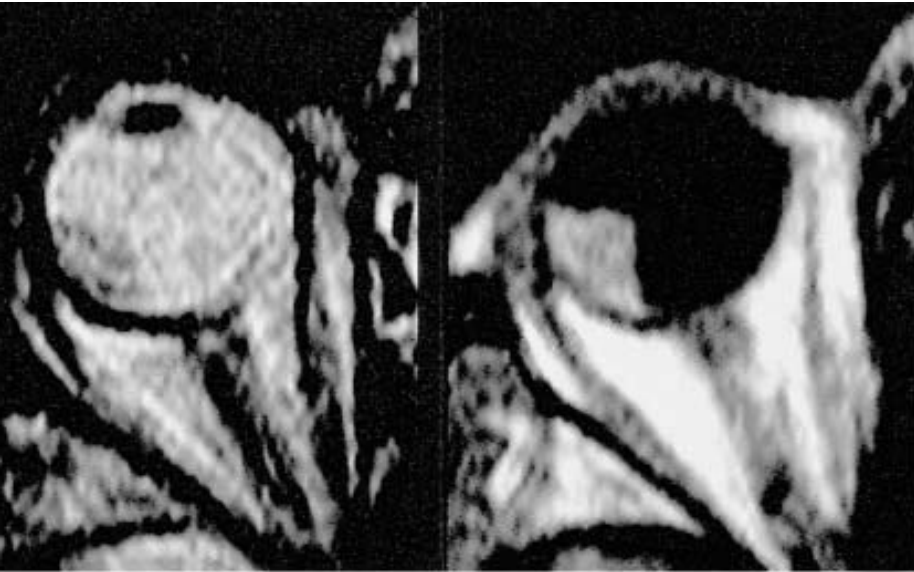


## Diagnostik: Ultraschall

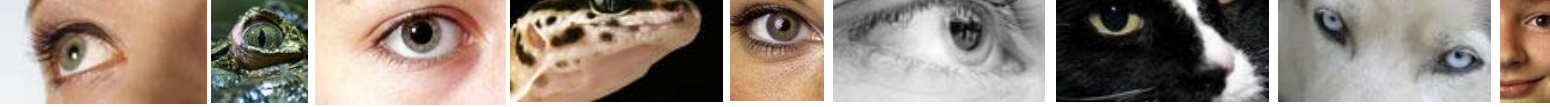




## Diagnostik: CT, NMR

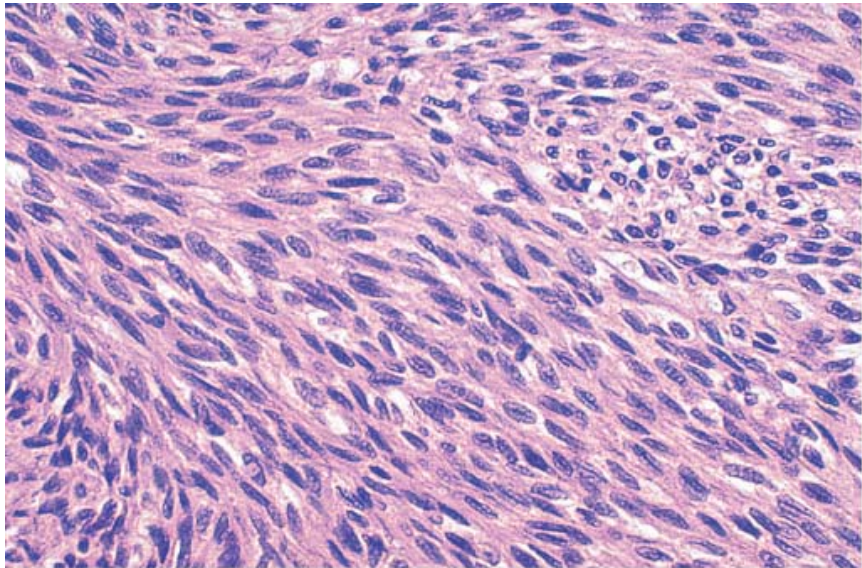




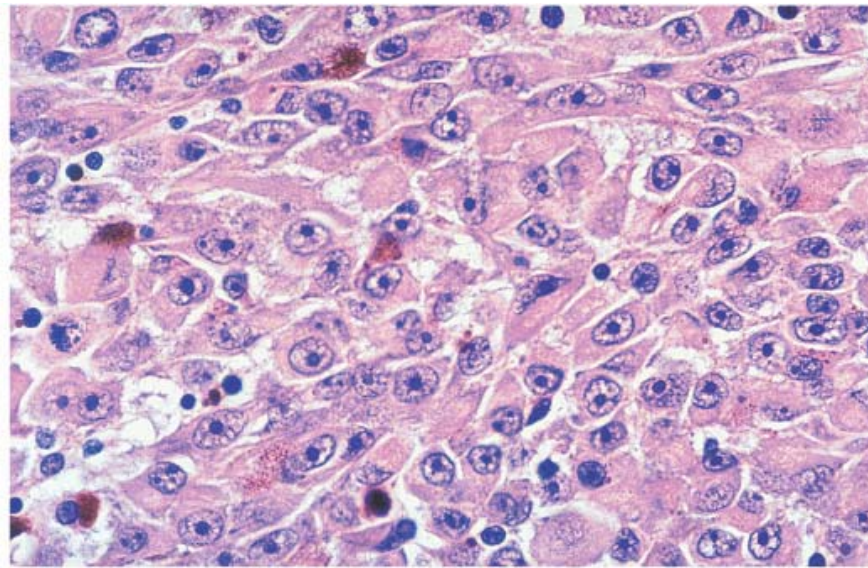


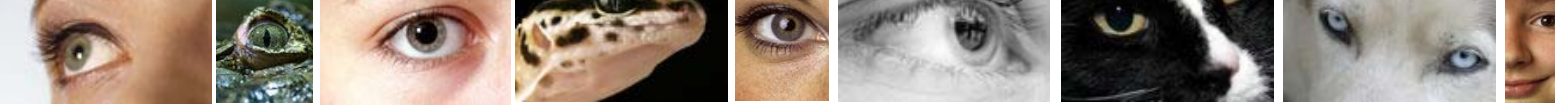
## ***Aderhautmelanom: Histologie***

Spindelzelltyp

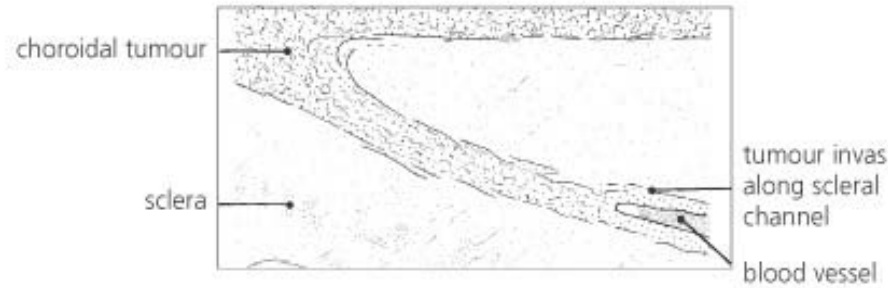
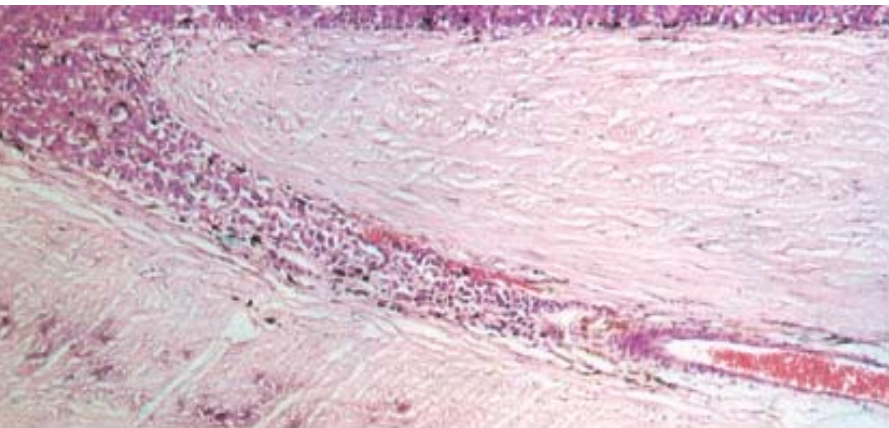


epitheloidzellig

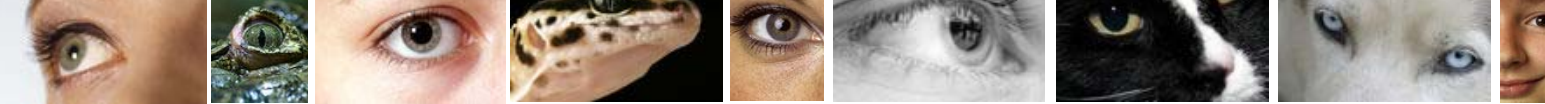




## ***Aderhautmelanom: Gefäßinvasion***







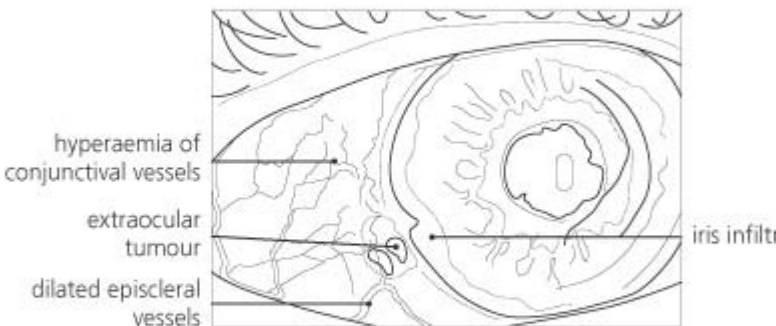
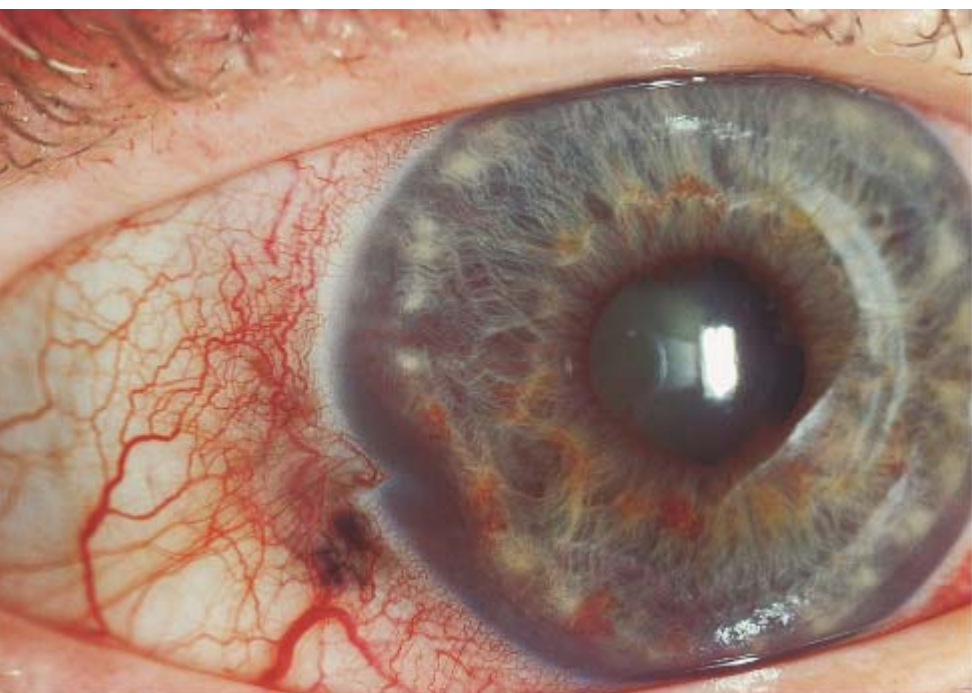# Skleradurchbruch !

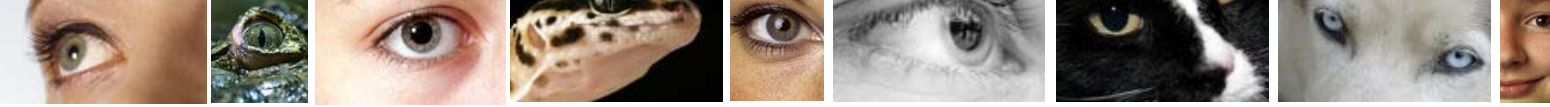
5 Jahresüberlebensrate: 40 - 80 %

Tumorgröße

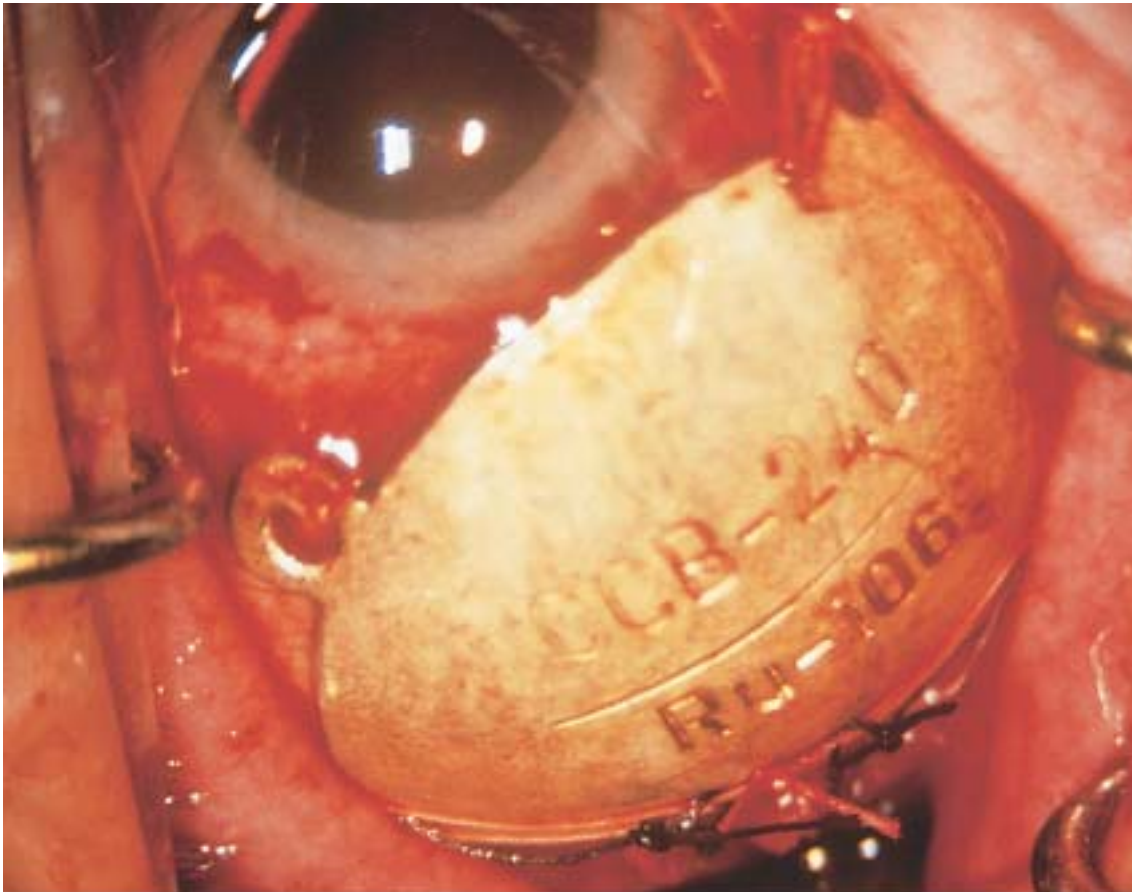
Histologie

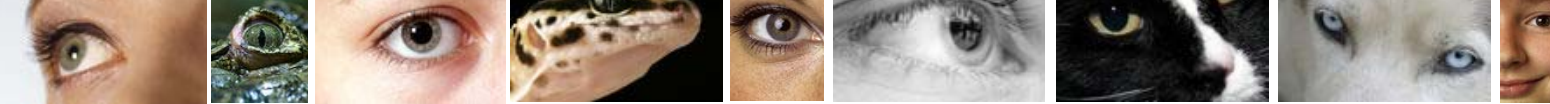
Chromosomale Abberation



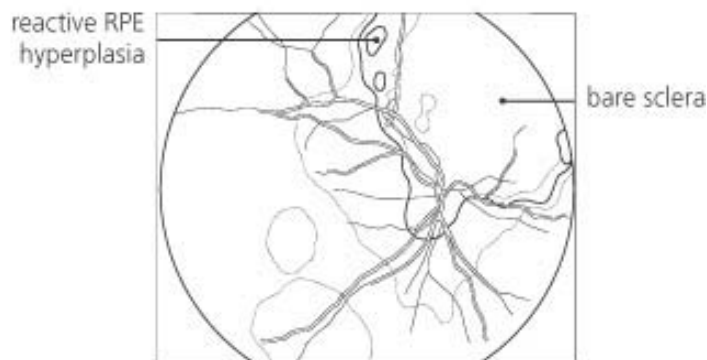
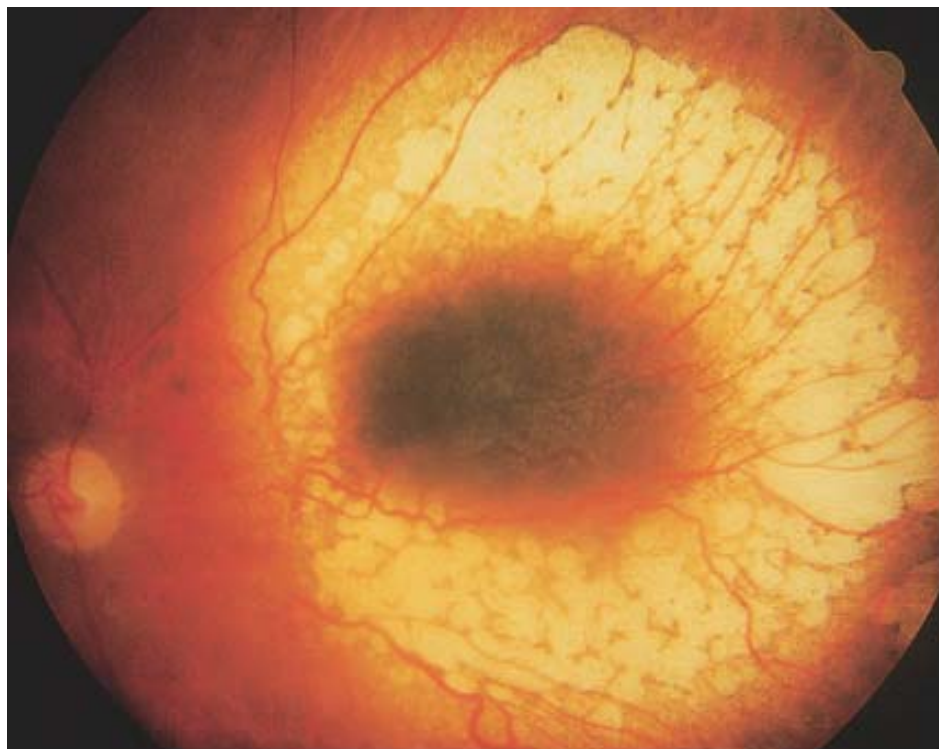

# **Therapieziel: Tumorkontrolle, hier Rutheniumbrachytherapi**

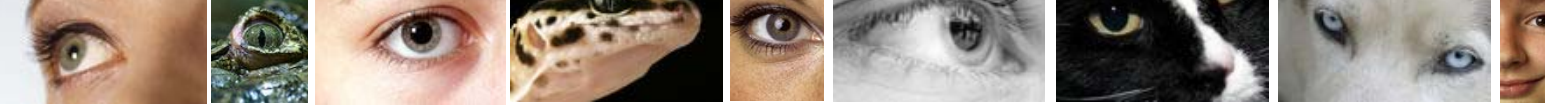




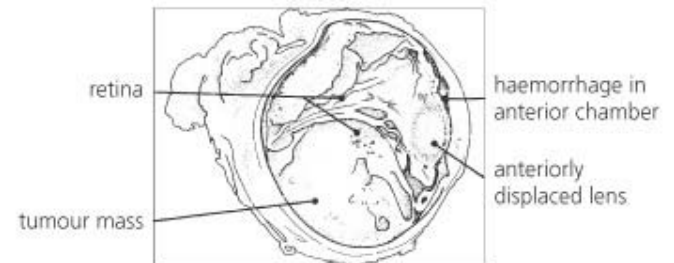
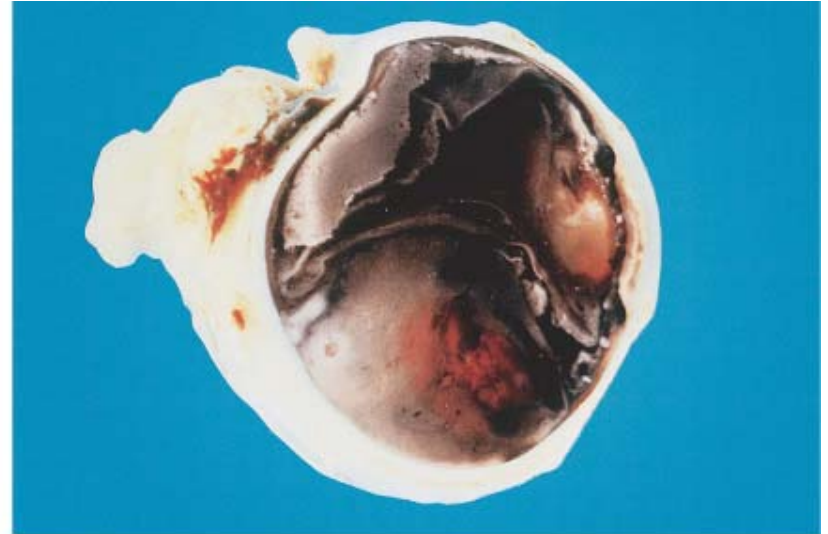
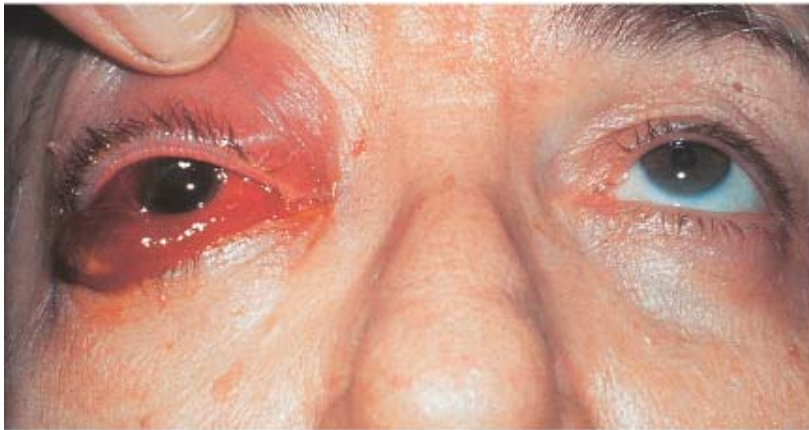## **Ergebnis nach lokaler Tumorbestrahlung mit Ru 106**

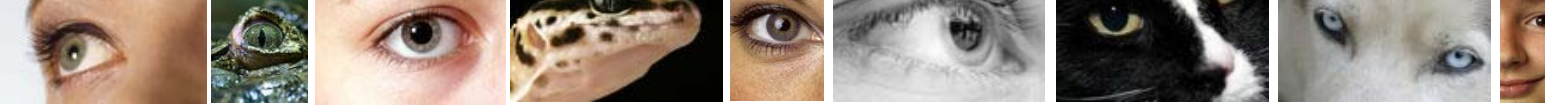






# ***Enukleation***

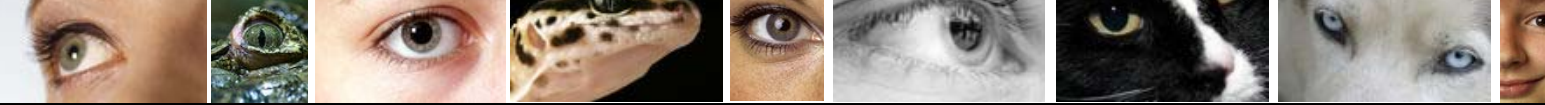




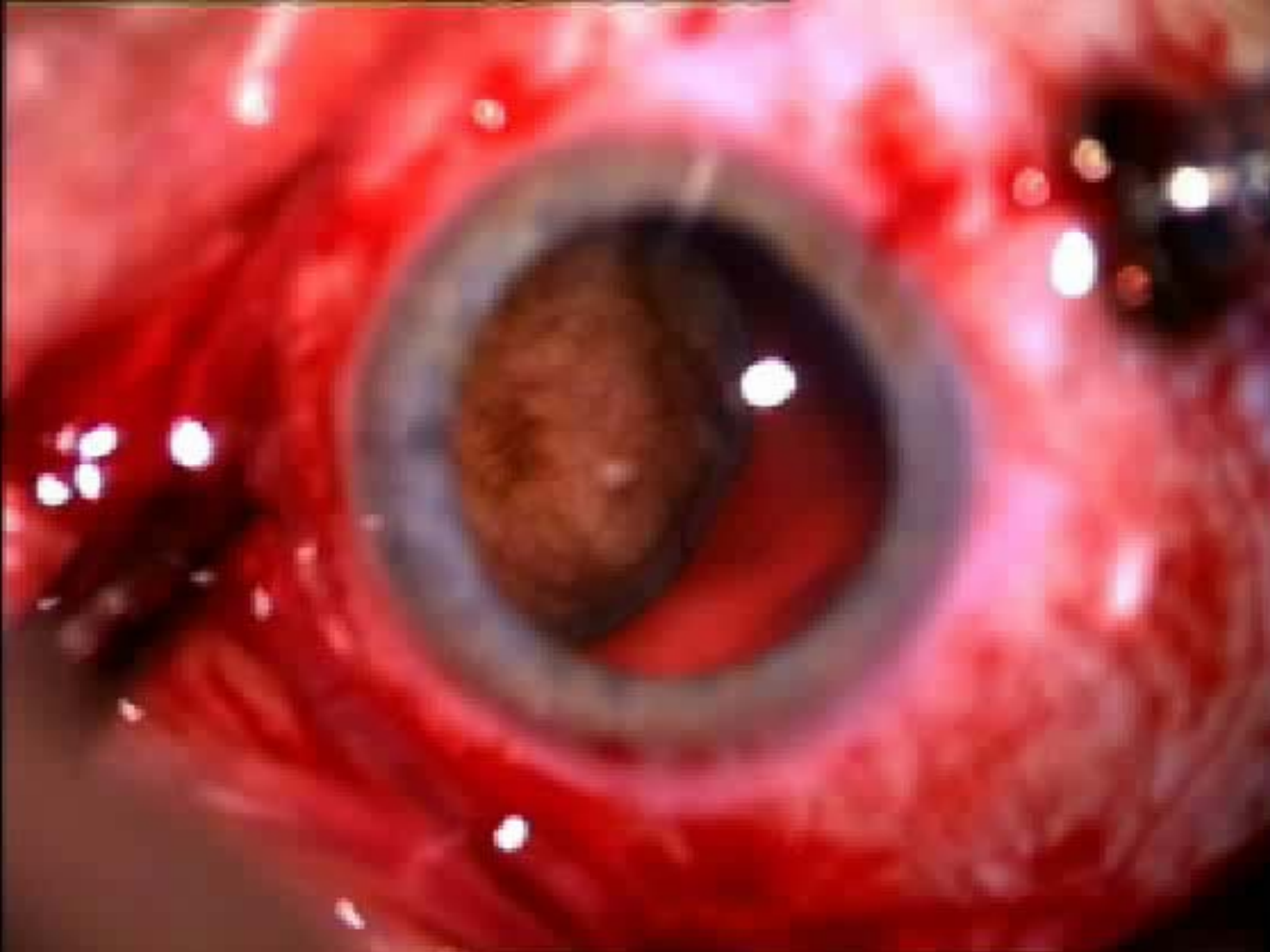
## ***Therapieverfahren-Aderhautmelanom-Übersicht***

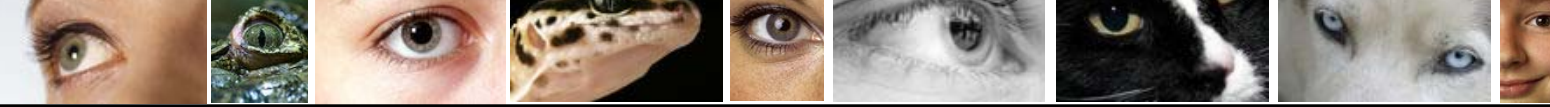
- **Enukleation**
- **Endo- oder Exoresektion**
- **Brachytherapie (Ru plaque)**
- **Thermotherapie**
- **Protonenbestrahlung**
- **Gamma Knife**
- **Beobachtung ?**



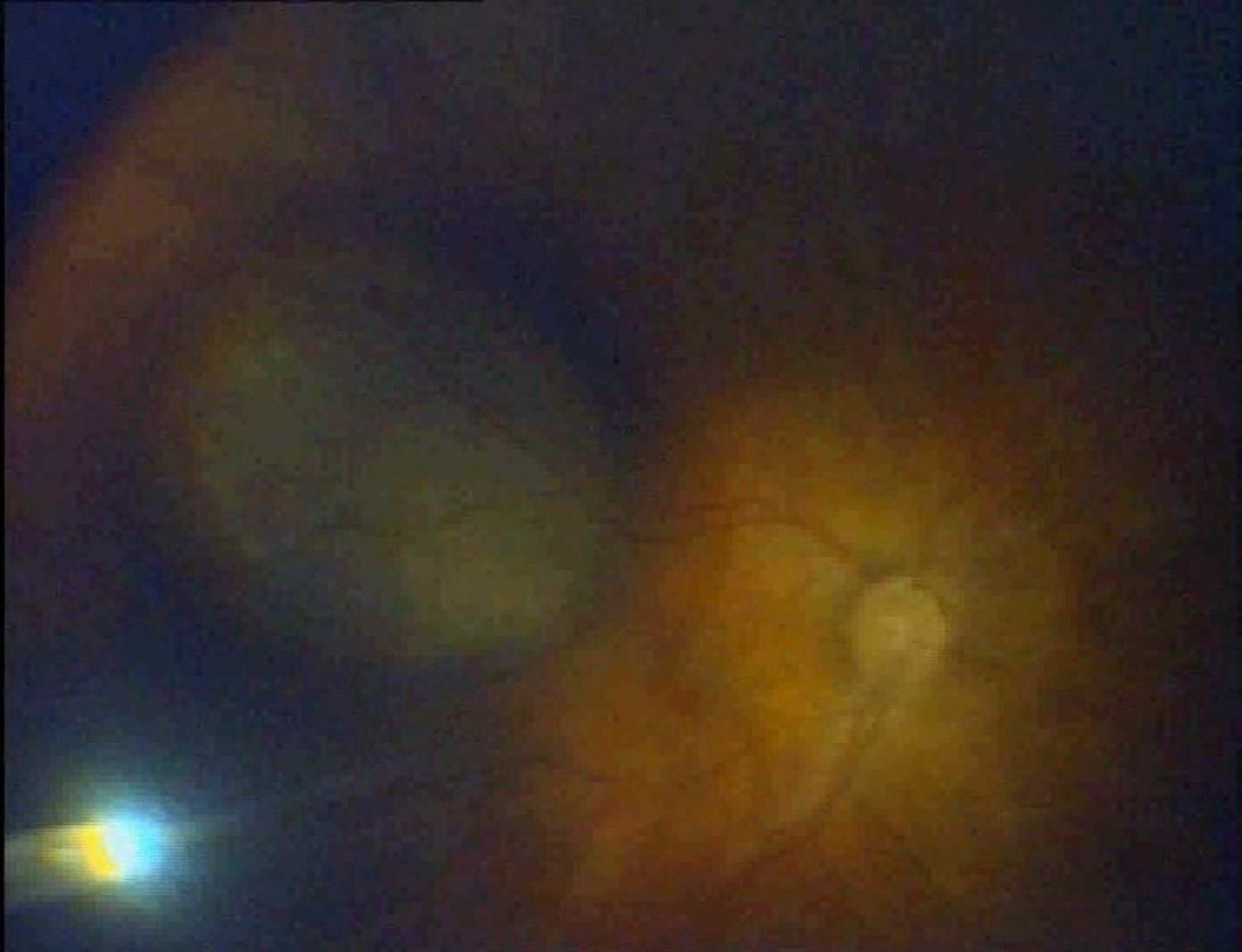

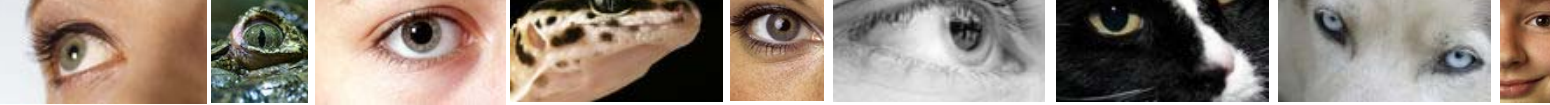
## ***Bulbuserhaltende Resektionsverfahren 1: Exoresektion***



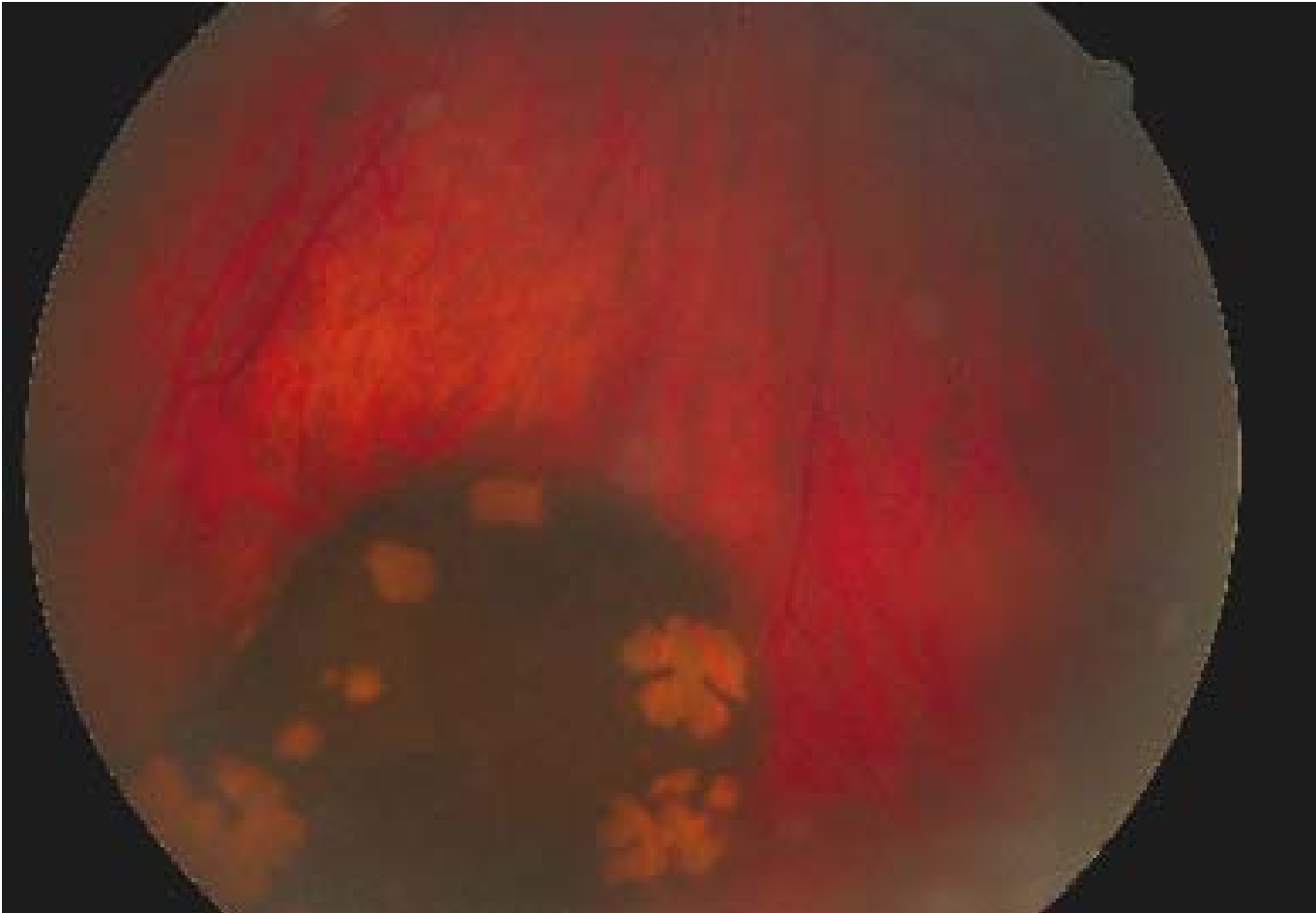


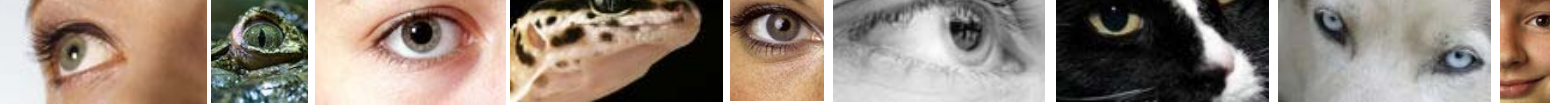
## ***Bulbuserhaltende Resektionsverfahren 2: Endoresektion***



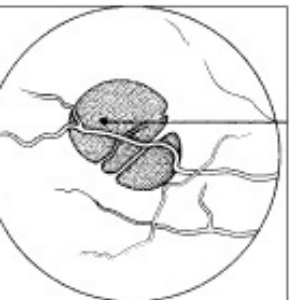
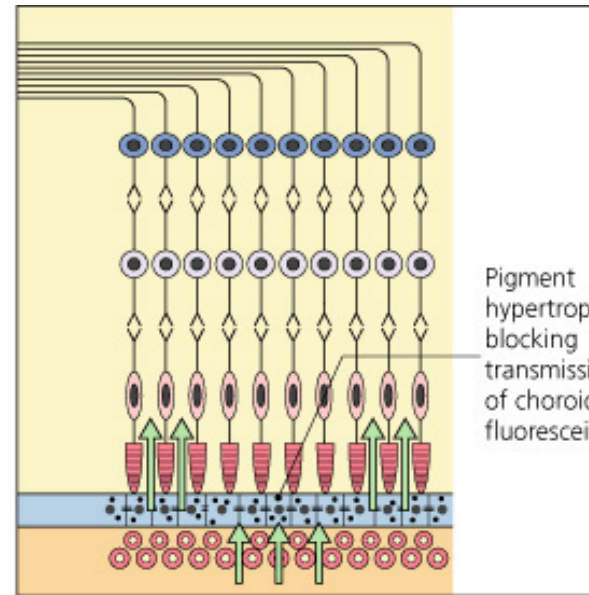
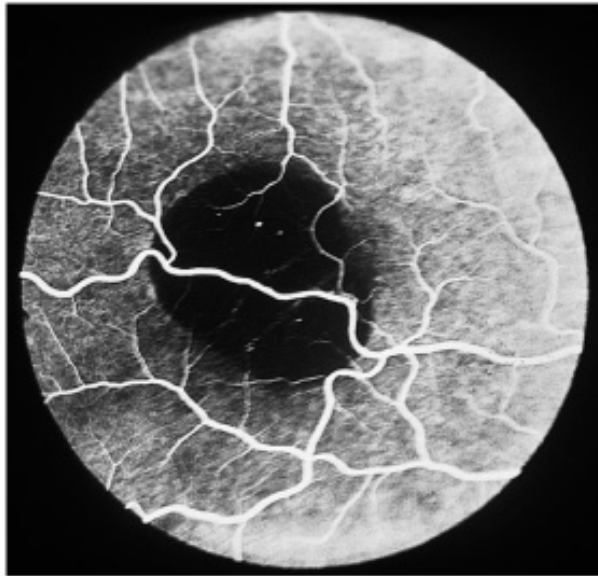
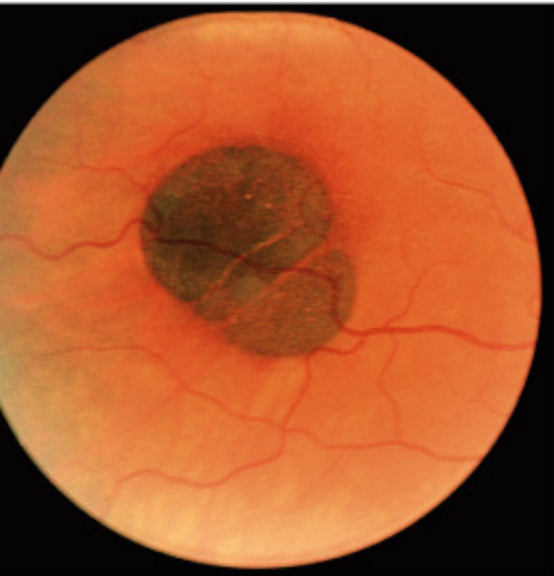
## Differentialdiagnose Tumoren Pigmentepithelhyperplasie

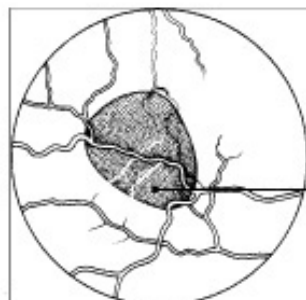



## Pigmentepithelhypertrophie

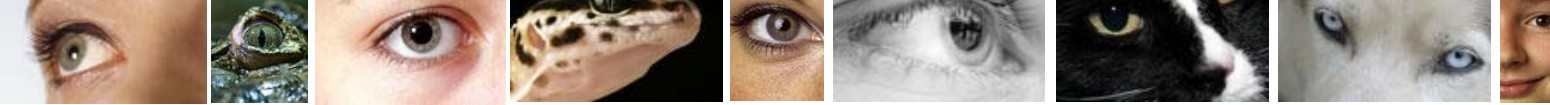


benign pigment epithelial hypertrophy

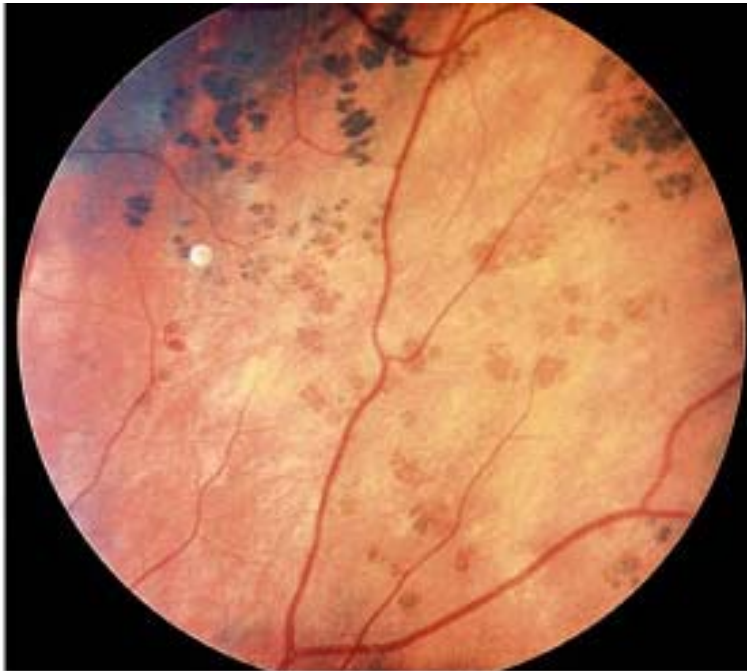


dense masking of choroidal fluorescence



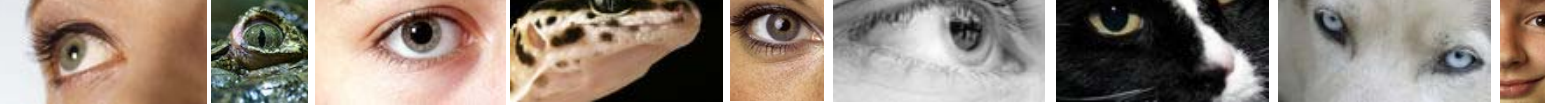


## ***Pigmentepithelhypertrophie: „Bärentatzen“***

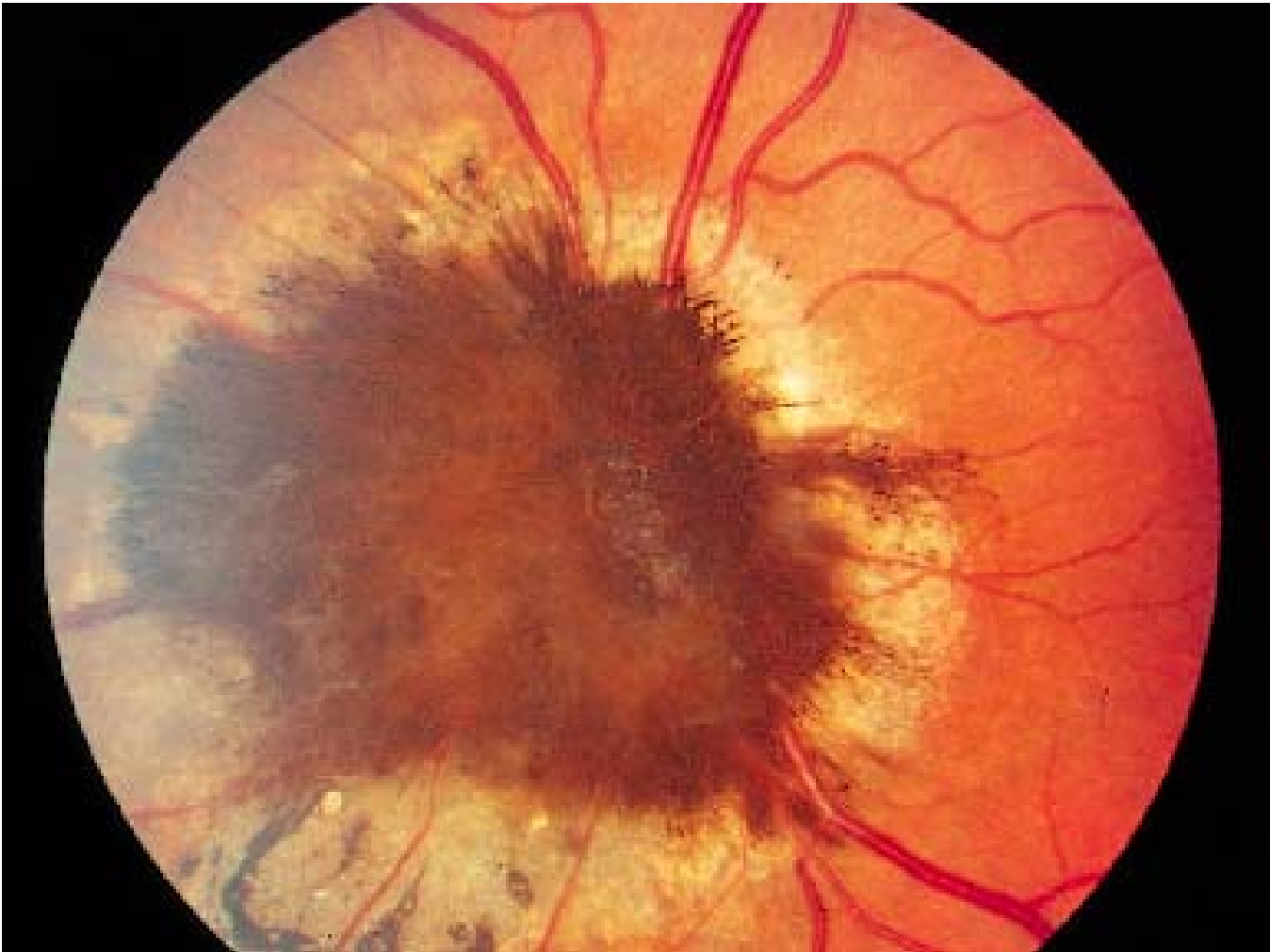


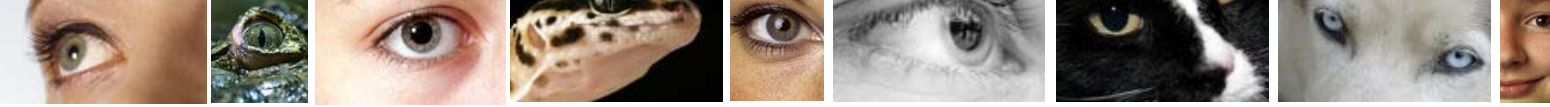
© 2005 Elsevier Ltd. Spalton et al: Atlas of Clinical Ophthalmology 3e



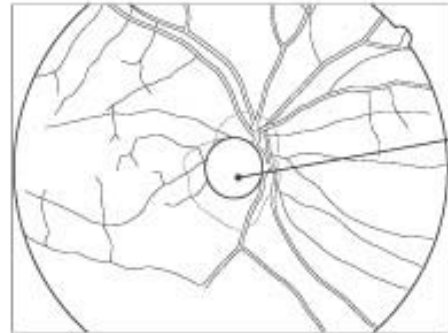
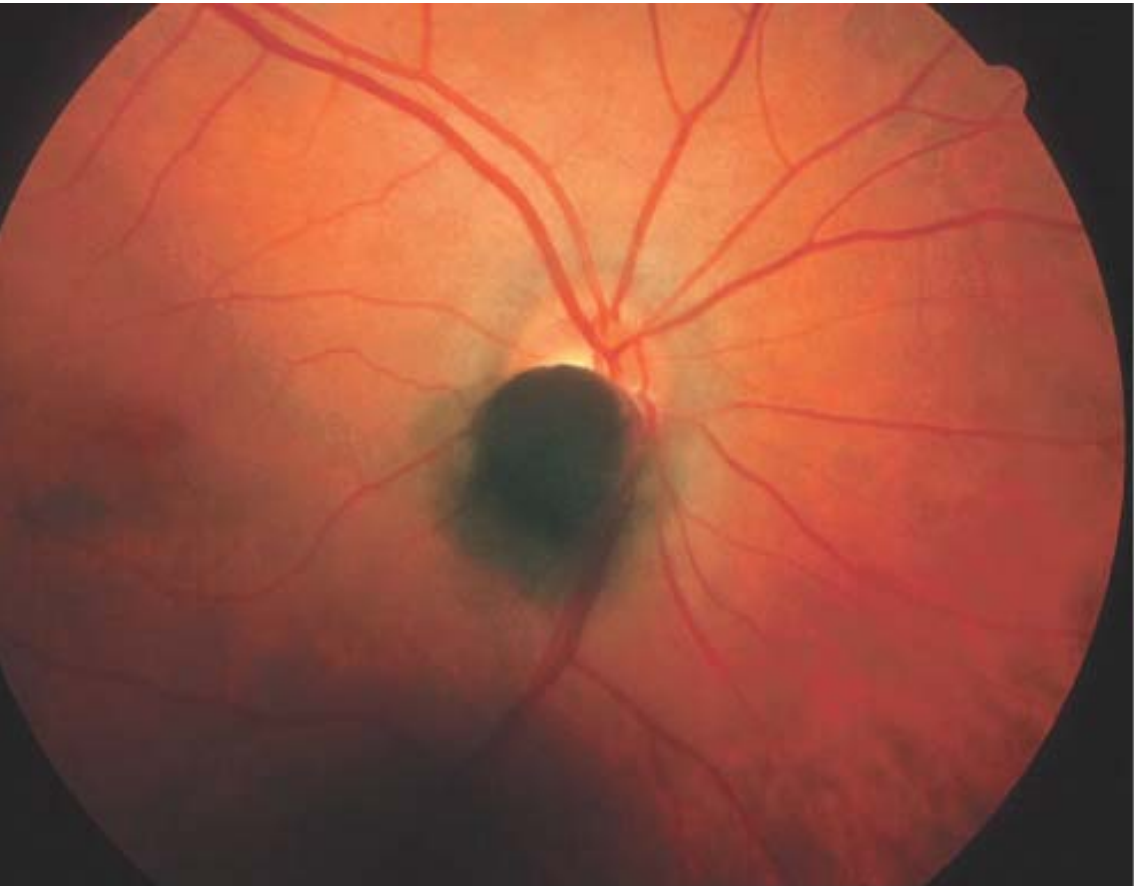


## ***DD Aderhautmelanom: Melanozytom der Papille***

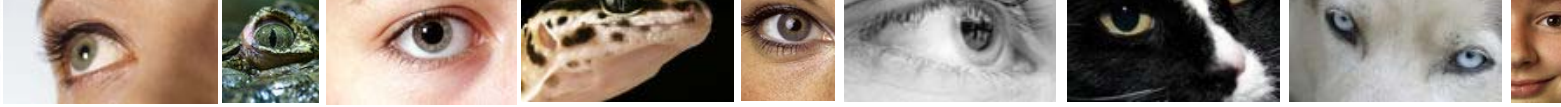




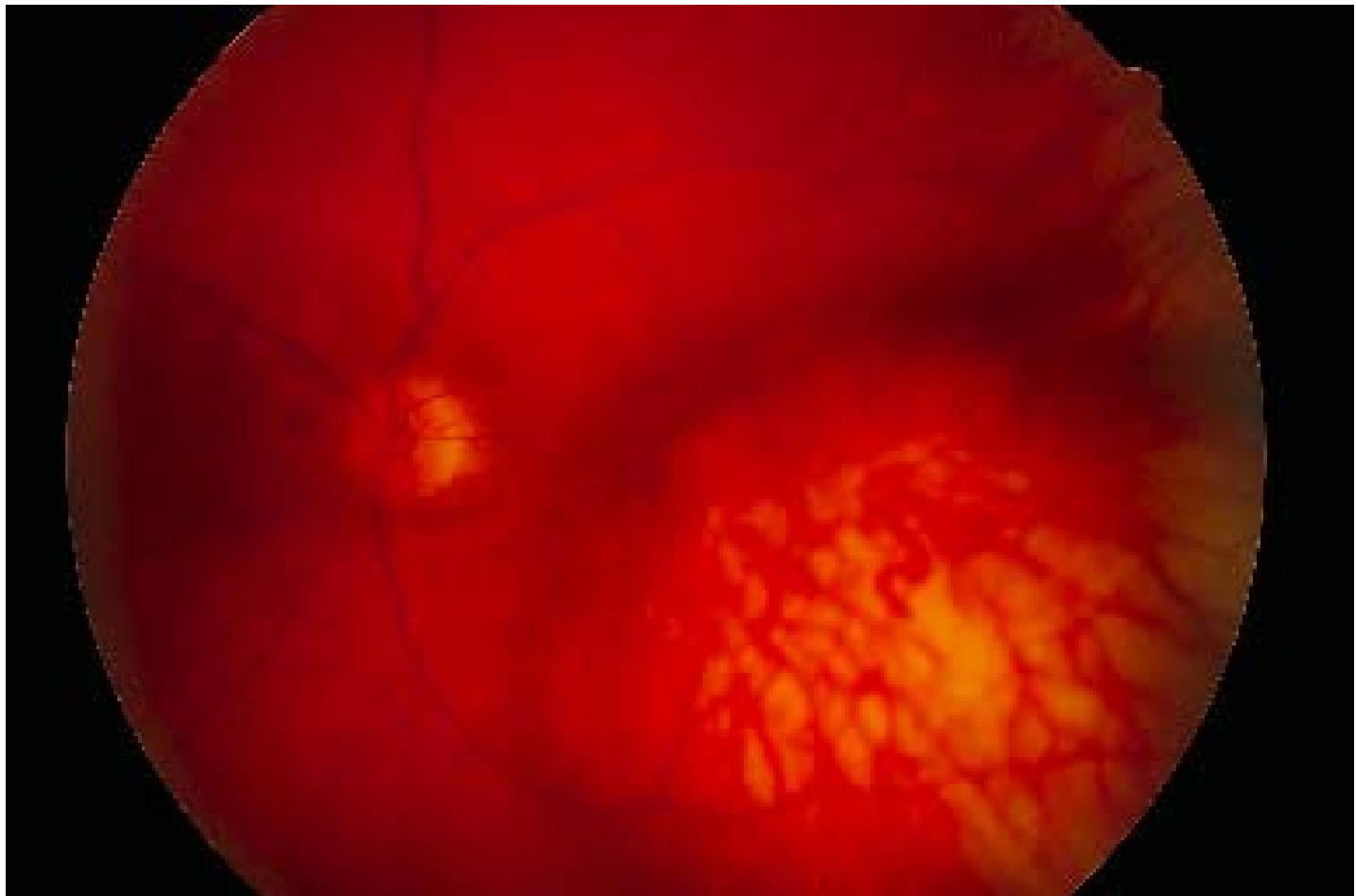
## ***DD Aderhautmelanom: Melanozytom der Papille***

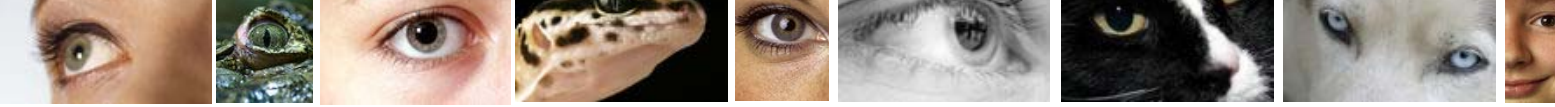


melanocytoma

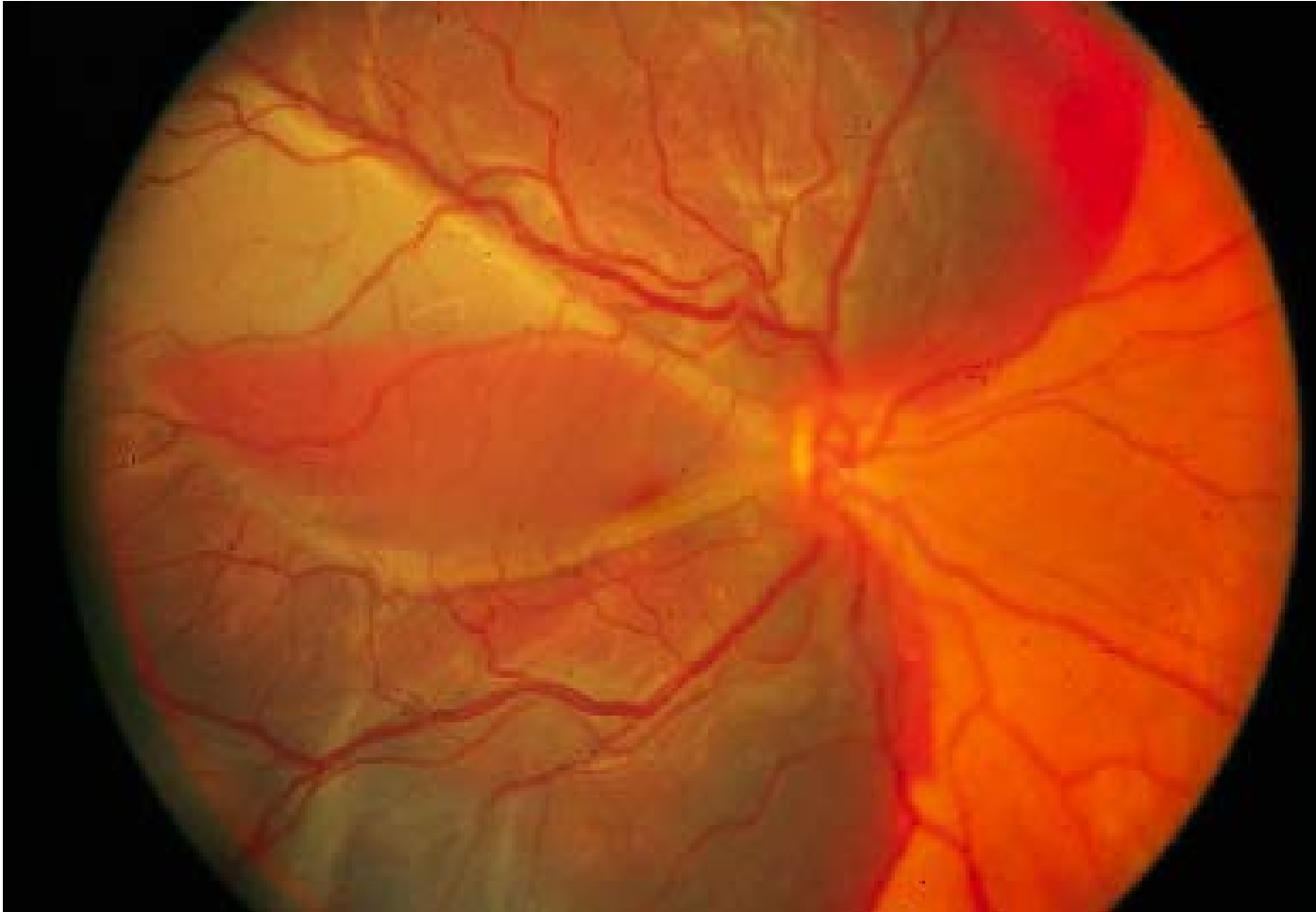


# ***DD Aderhautmelanom: Amelanotisches Melanom***

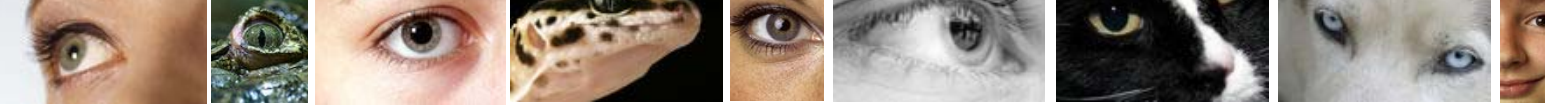




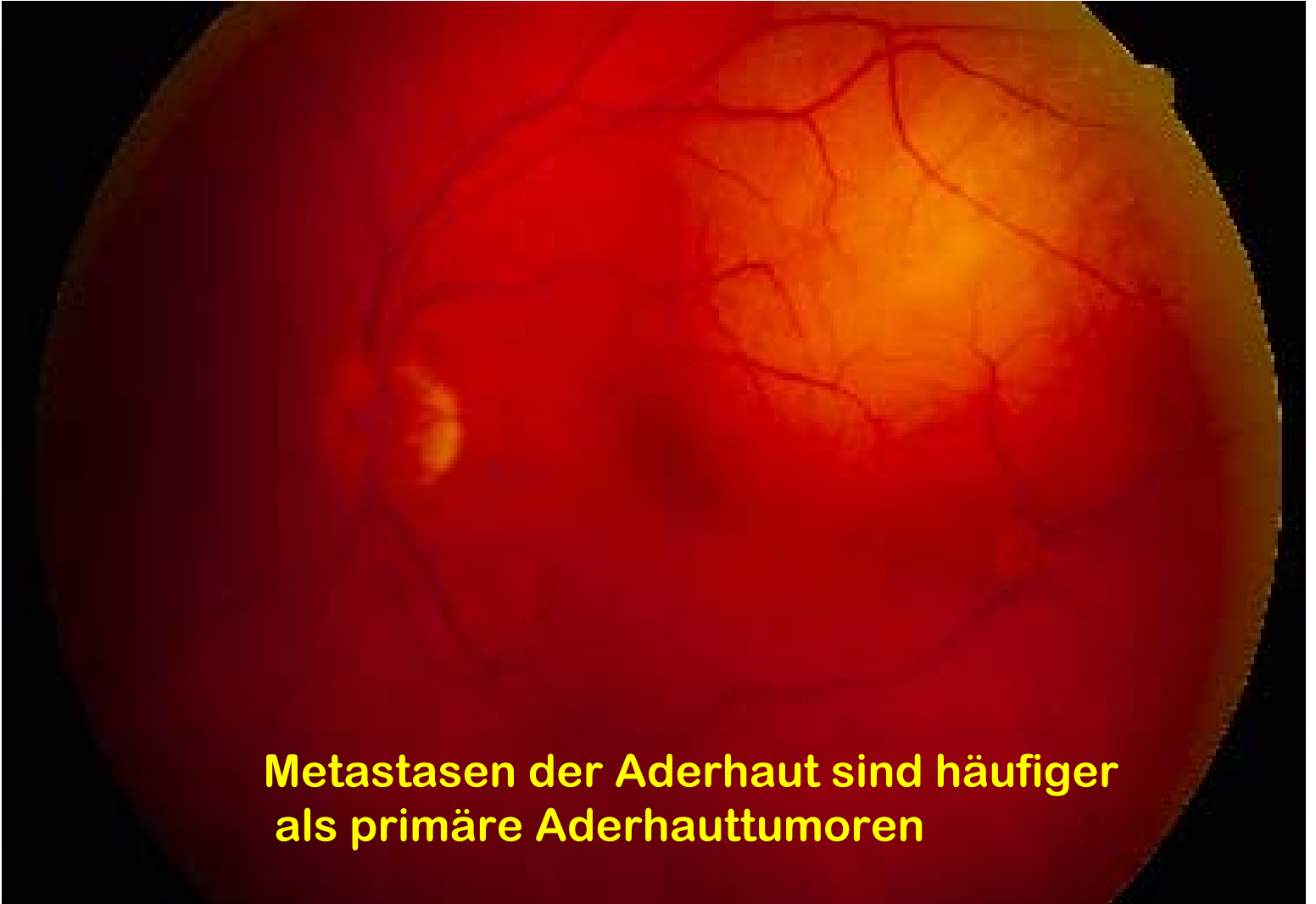# Differentialdiagnose Tumoren massive subretinale Butung, z.B. Marcumar bei AMD



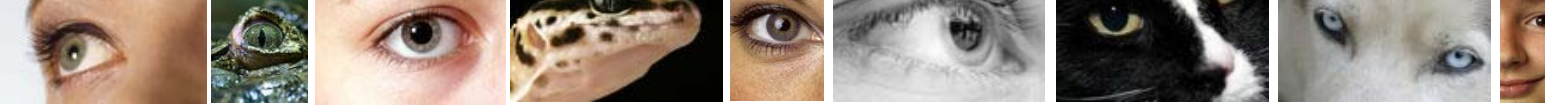




## ***Aderhautmetastasen: Bronchialca, Mammaca, Lymphome***



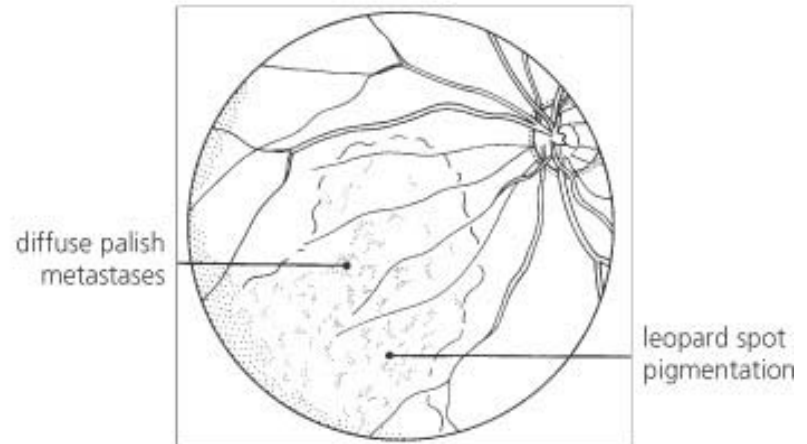
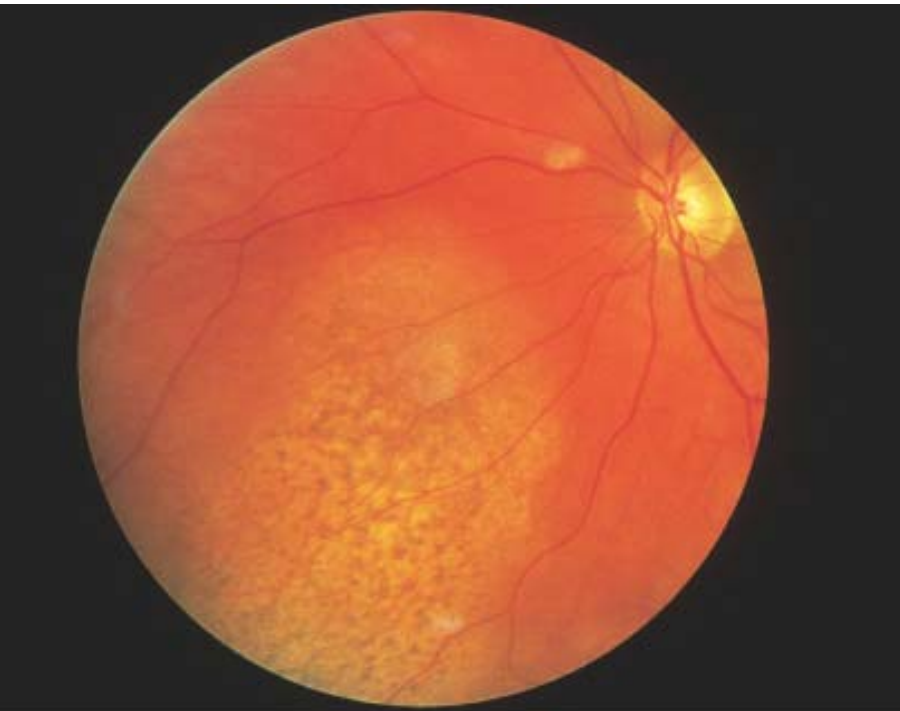**Metastasen der Aderhaut sind häufiger  
als primäre Aderhauttumoren**

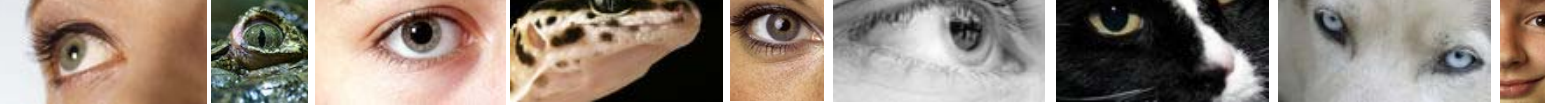


## Aderhautmetastase

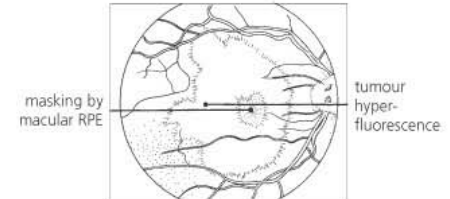
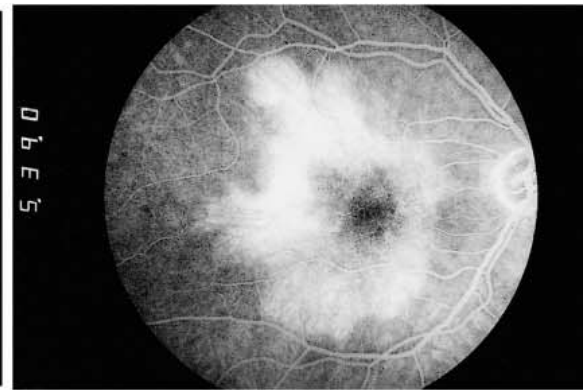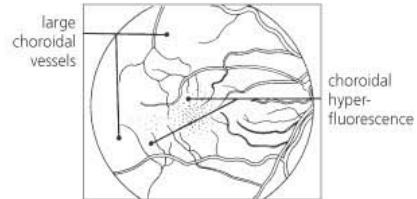
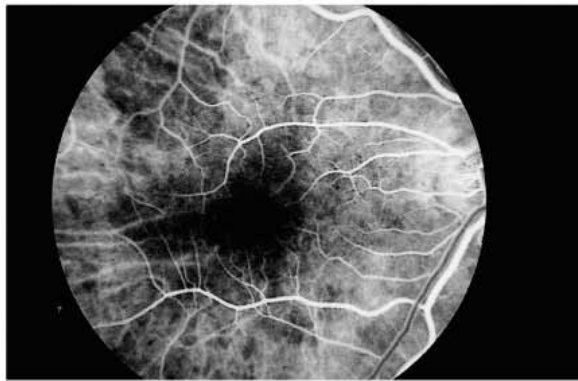
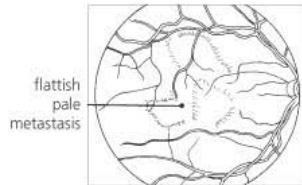
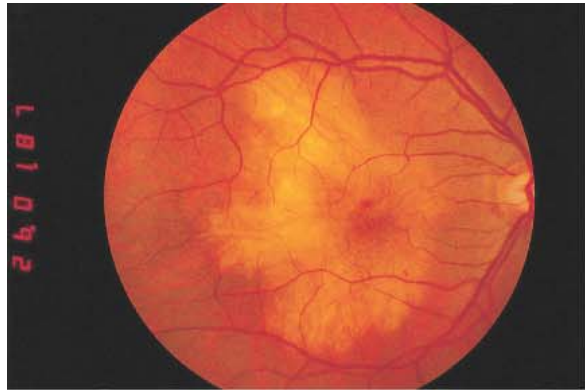
Häufigkeit maligner intraokularer Tumore:

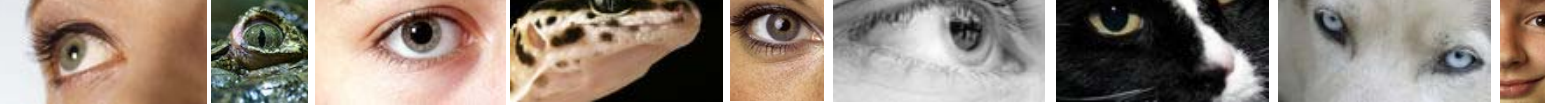
1. AH-Metastasen (10 % aller Malignome)
2. AH-Melanome



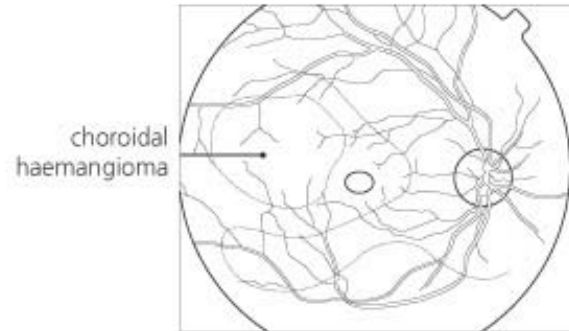
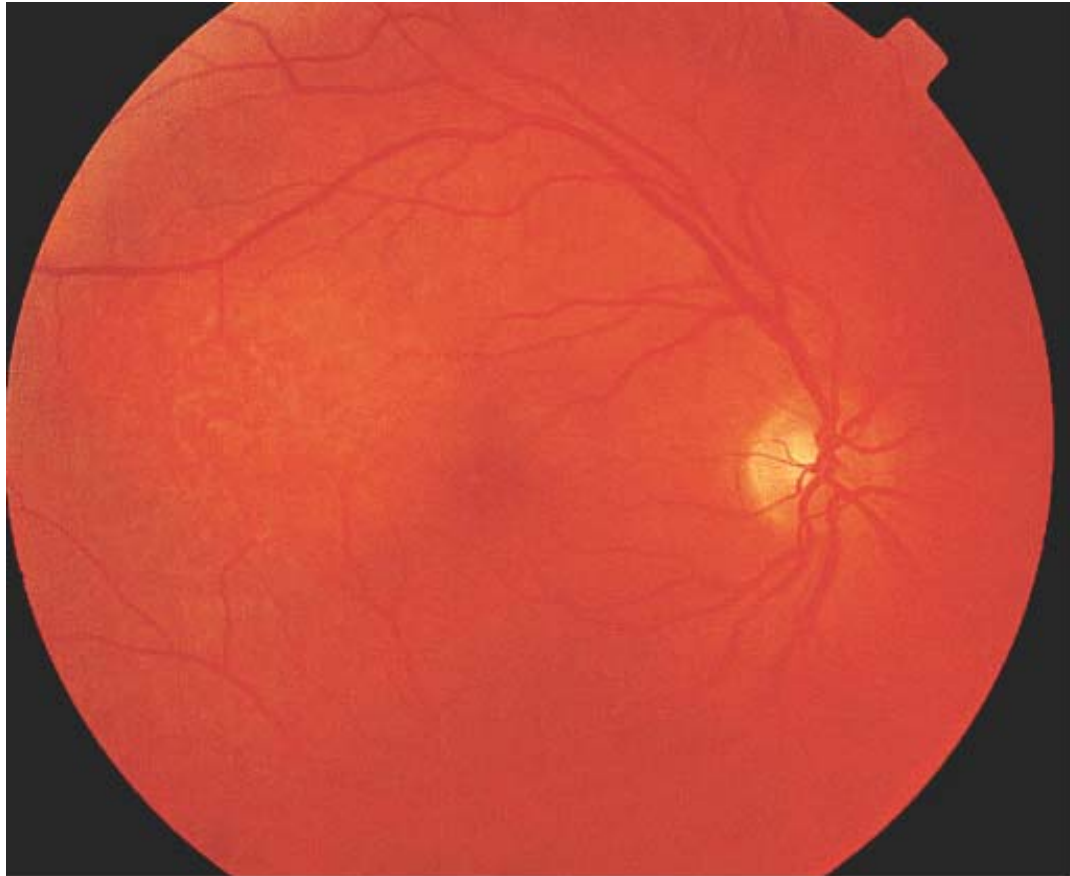

## Aderhautmetastase

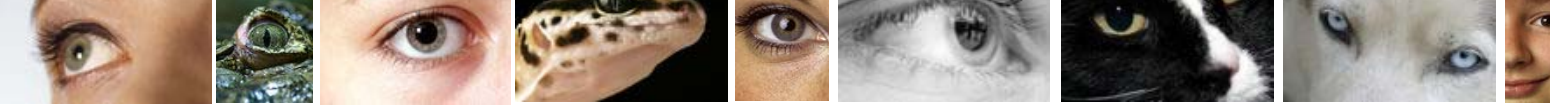




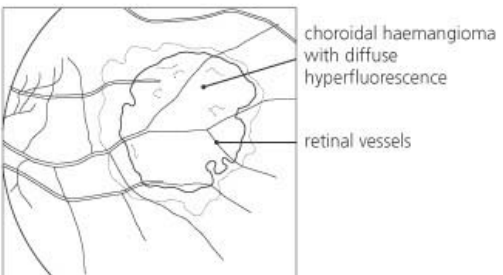
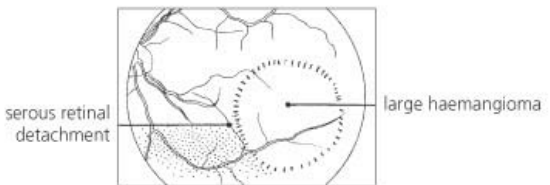
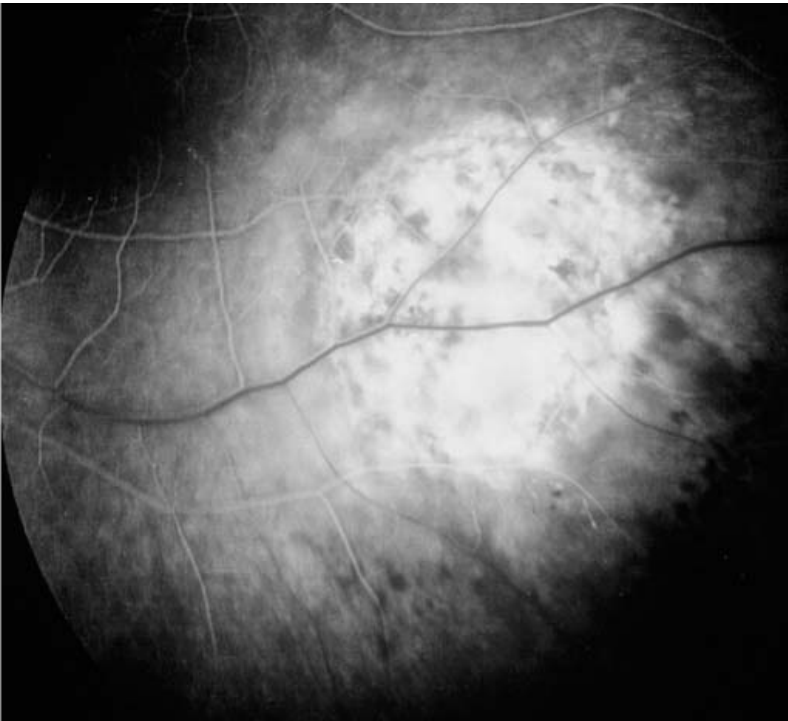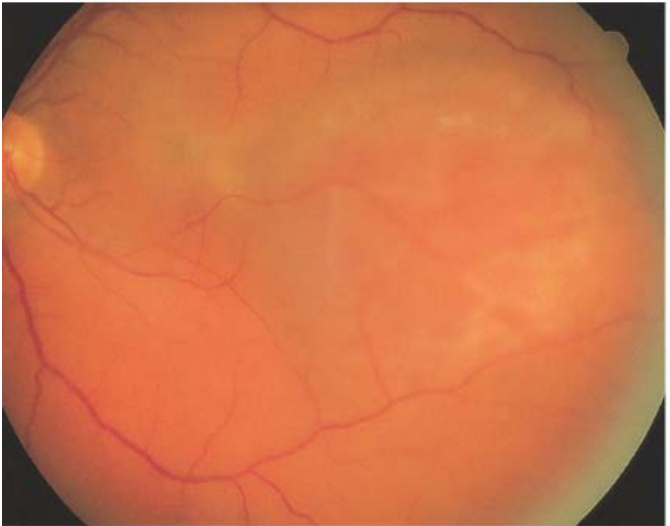
## ***Hämangiom der Aderhaut***

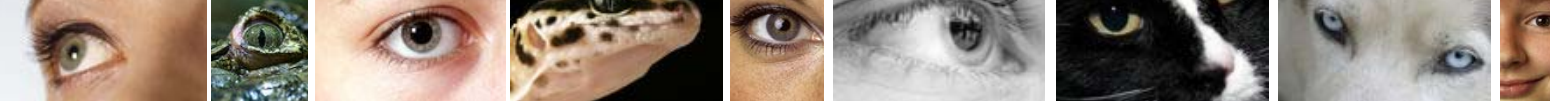



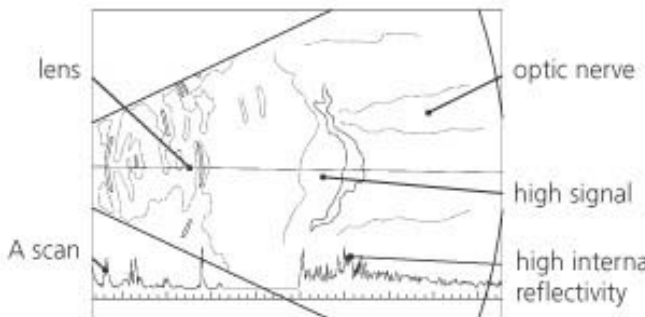
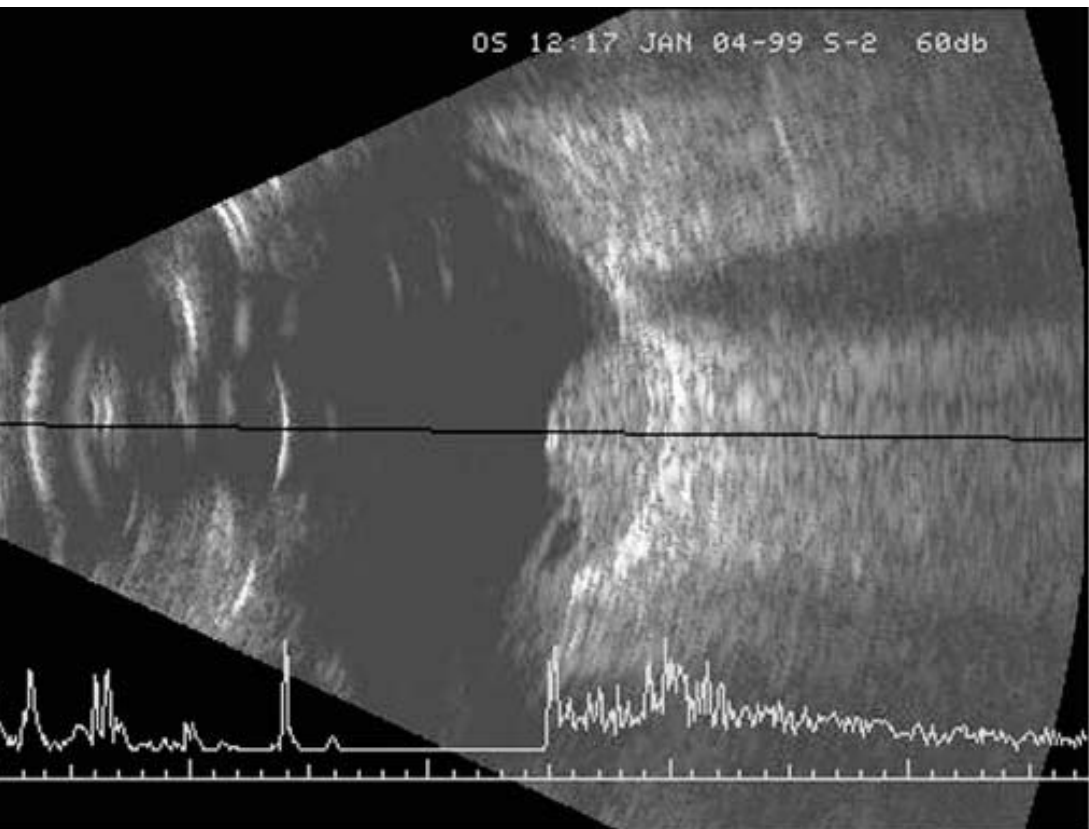


# Hämangiom der Aderhaut



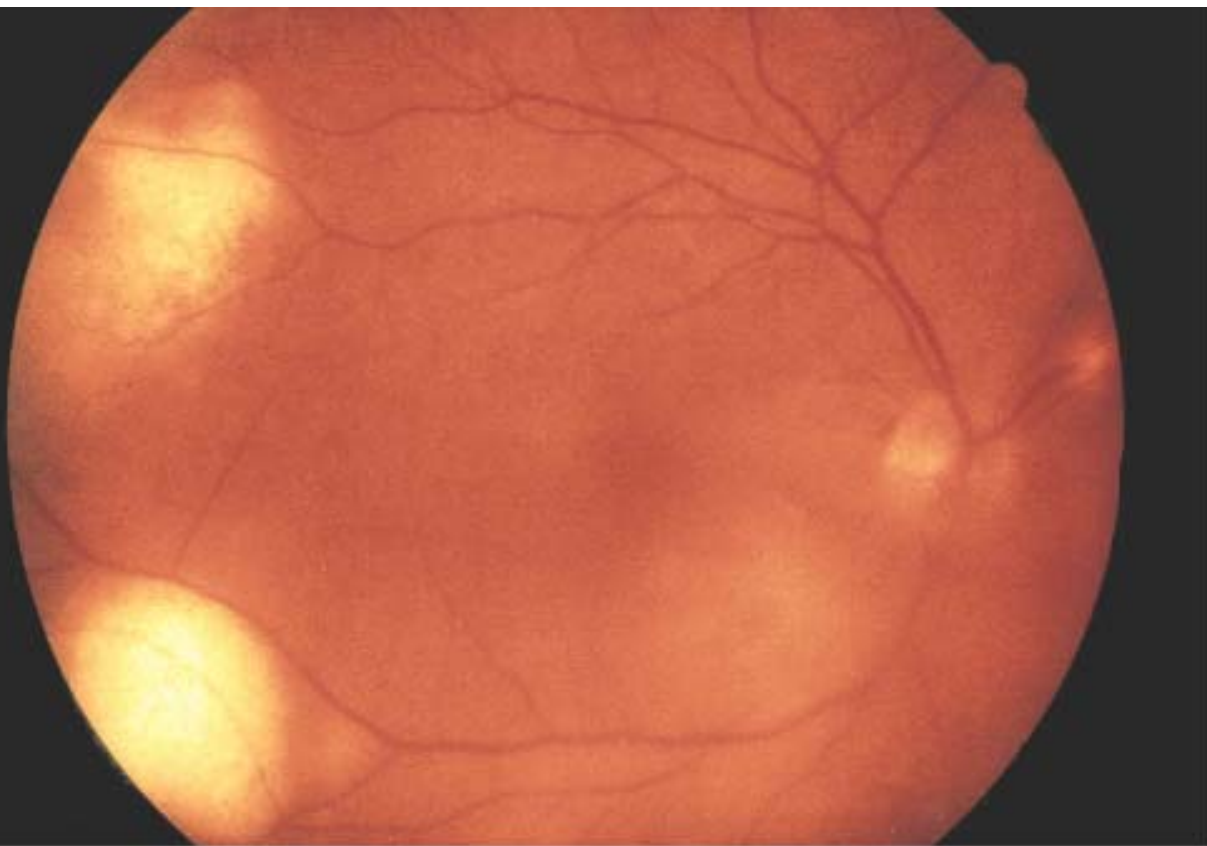

## Hämangiom der Aderhaut



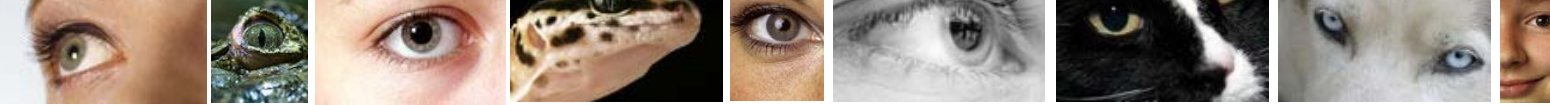


## ***Okuläres Lymphom***

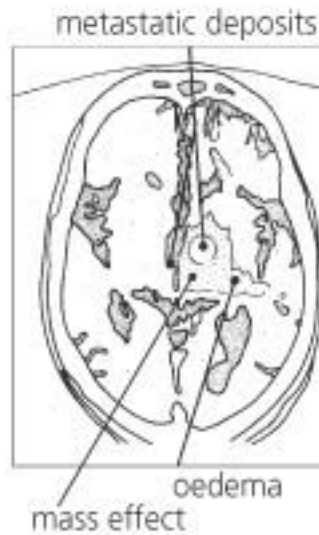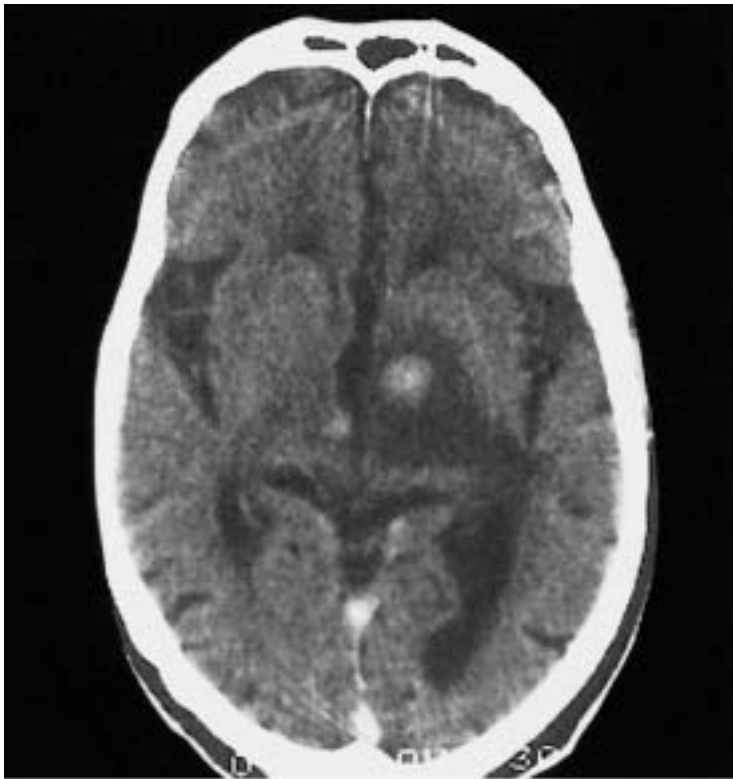


subretinal masses

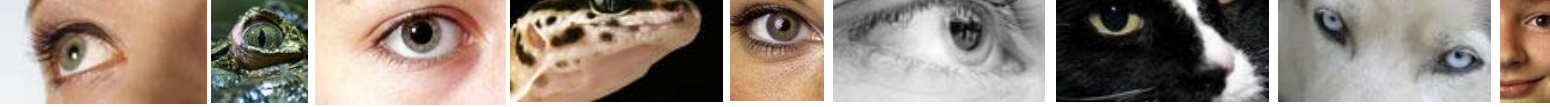




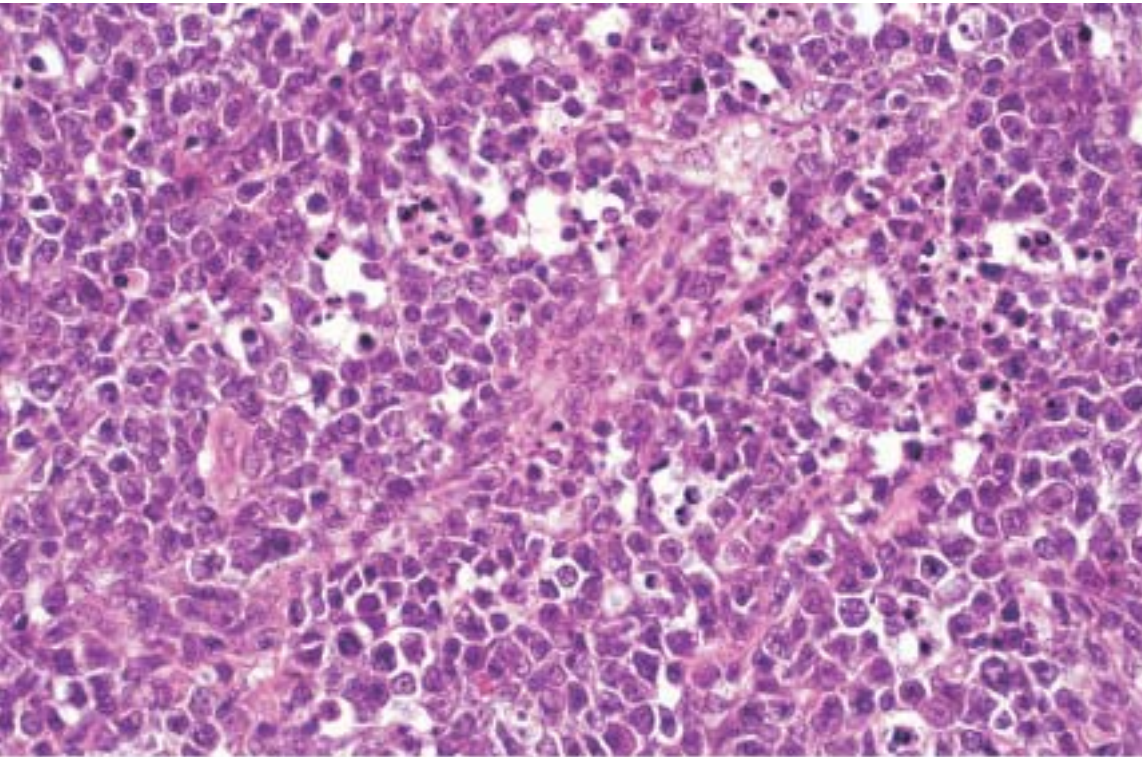
## ***Okuläres Lymphom mit Hirnbeteiligung***



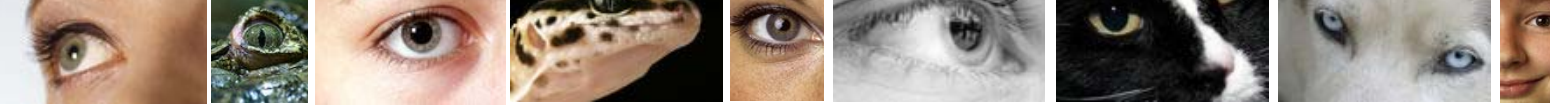




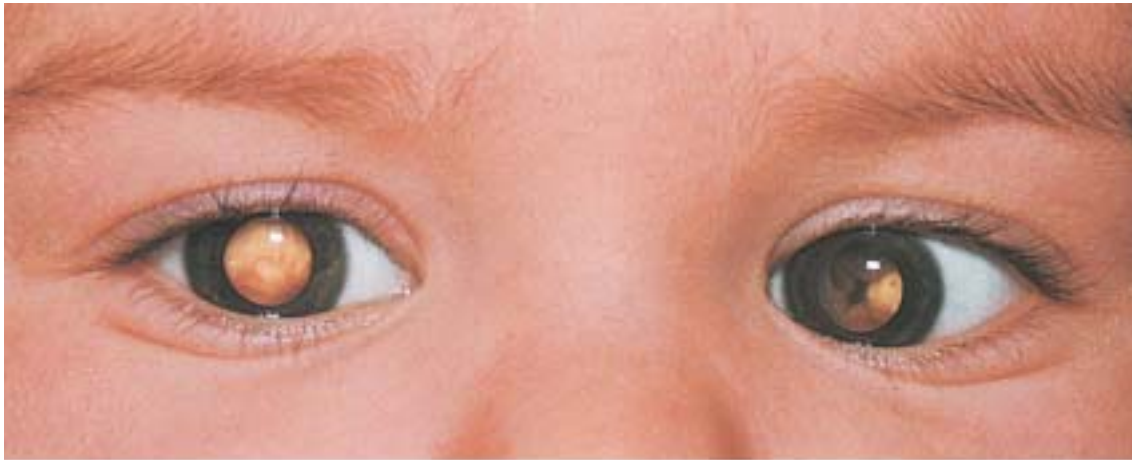## ***Okuläres Lymphom : Histologie***



© 2005 Elsevier Ltd. Spalton et al: Atlas of Clinical Ophthalmology 3e



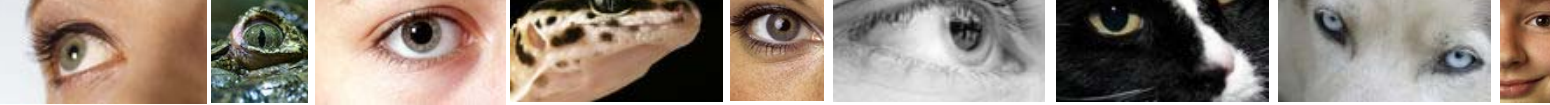
# **Leukokorie**



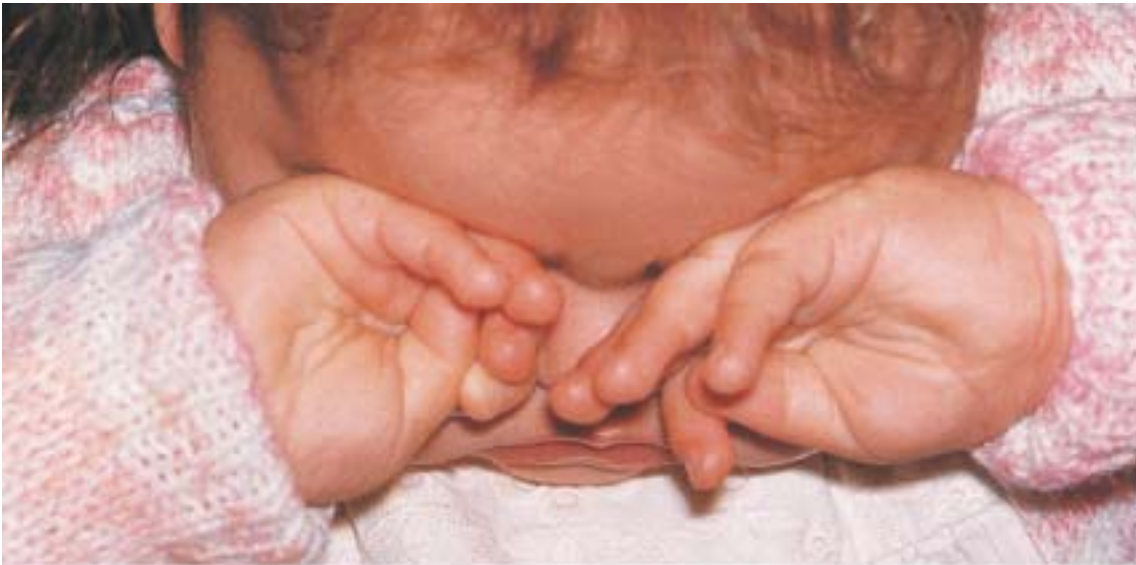© 2005 Elsevier Ltd. Spalton et al: Atlas of Clinical Ophthalmology 3e

Differentialdiagnose:

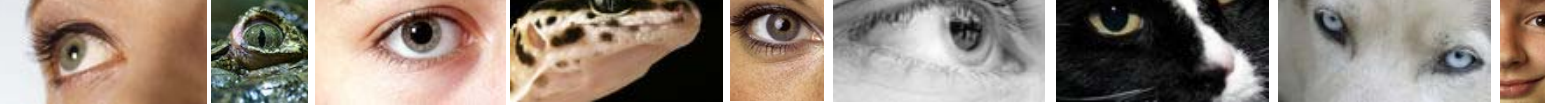
- Retinoblastom
- M. Coats
- kong. Katarakt
- PHPV / PFV Syndrom
- Uveitis
- ROP



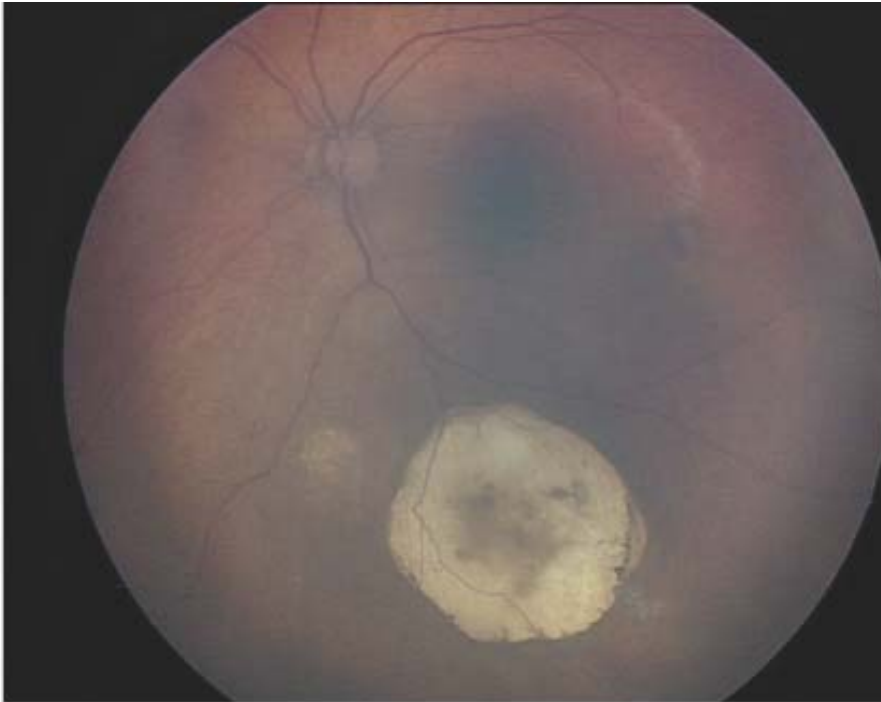
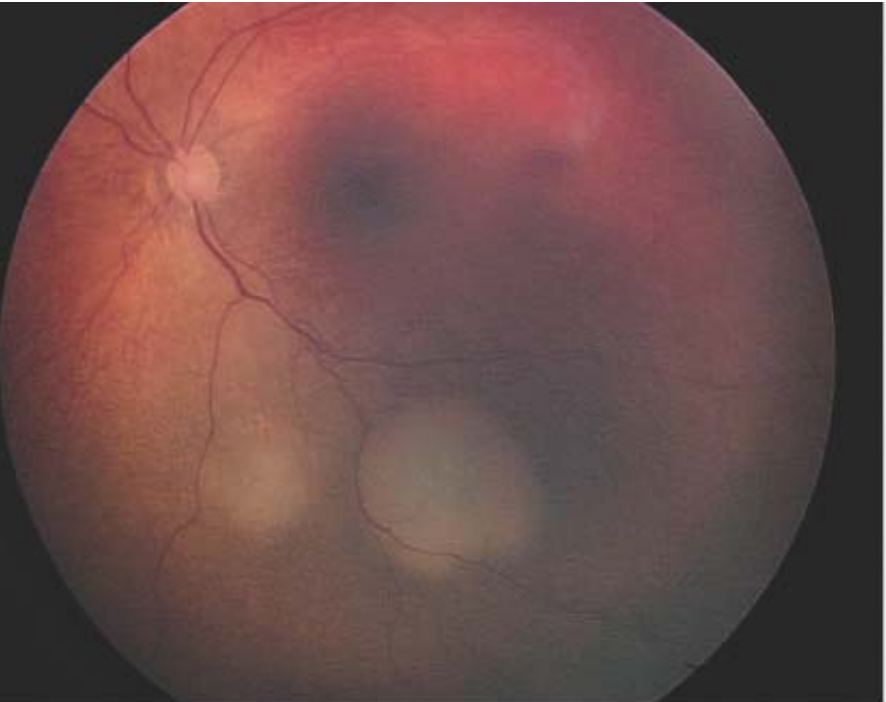
## ***Okulodigitales Phänomen***



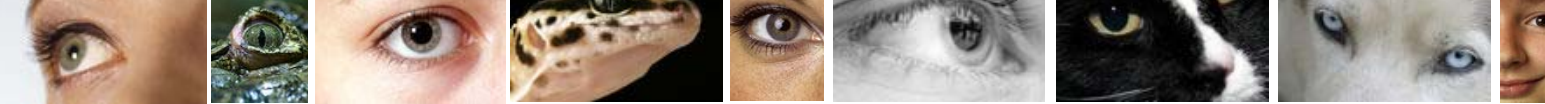
© 2005 Elsevier Ltd. Spalton et al: Atlas of Clinical Ophthalmology 3e



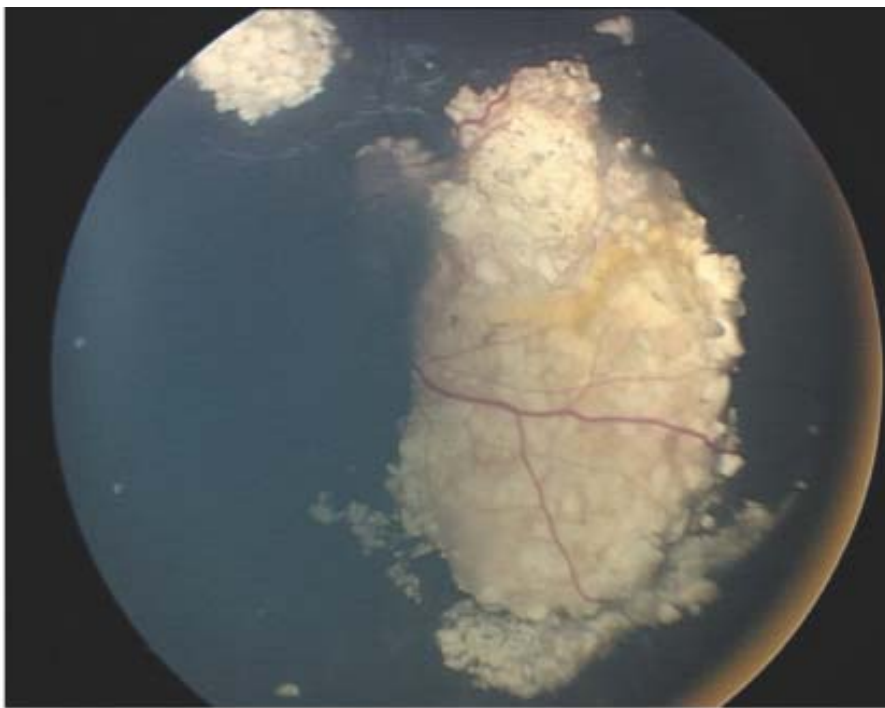
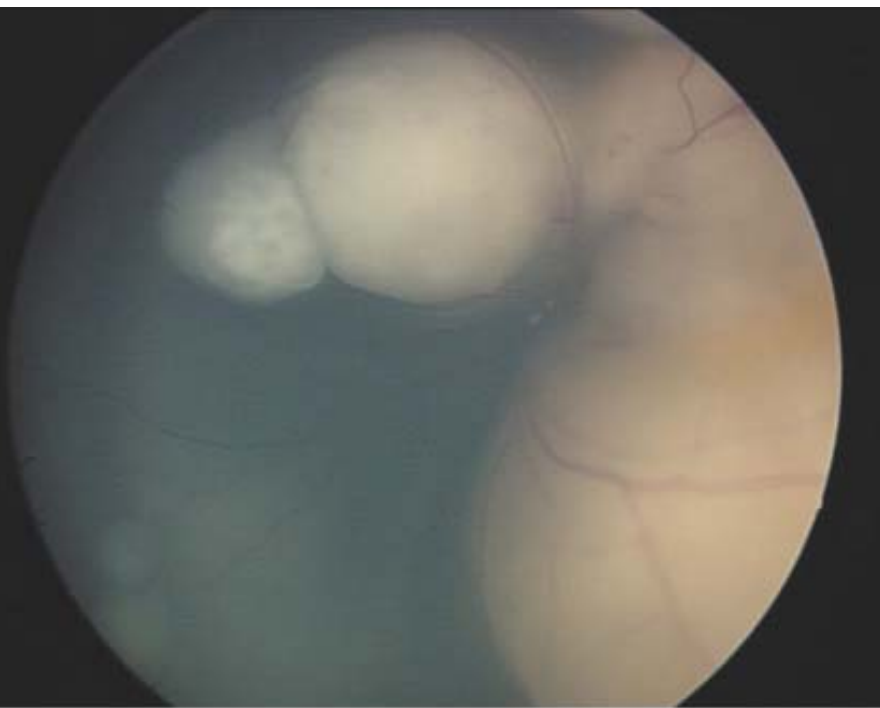
## ***Retinoblastom: hier endophytische parazentrale Form***

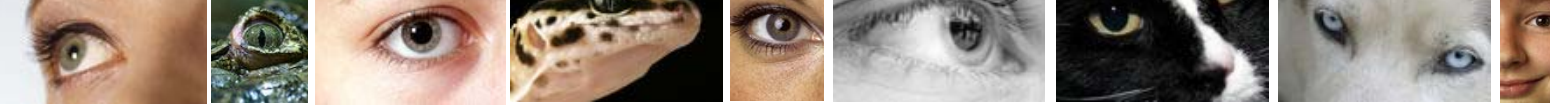




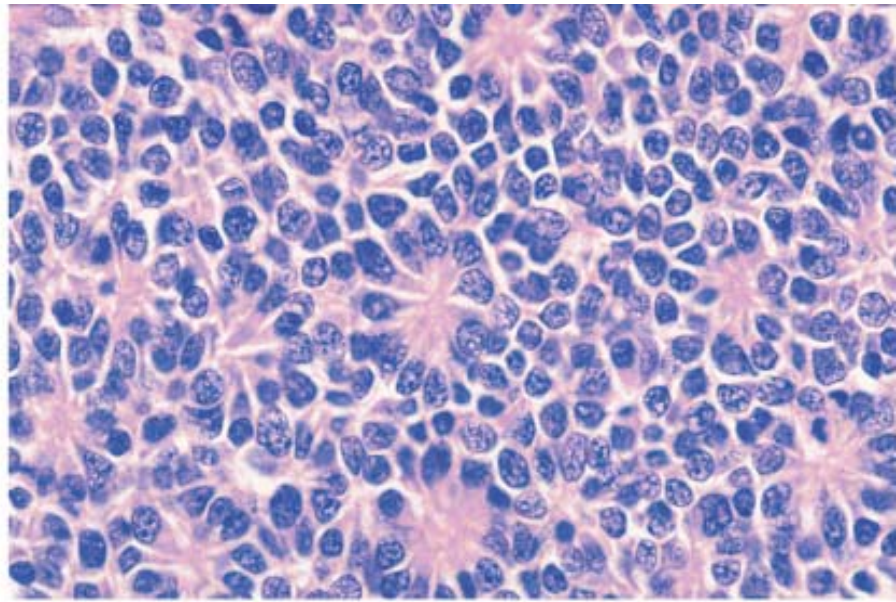
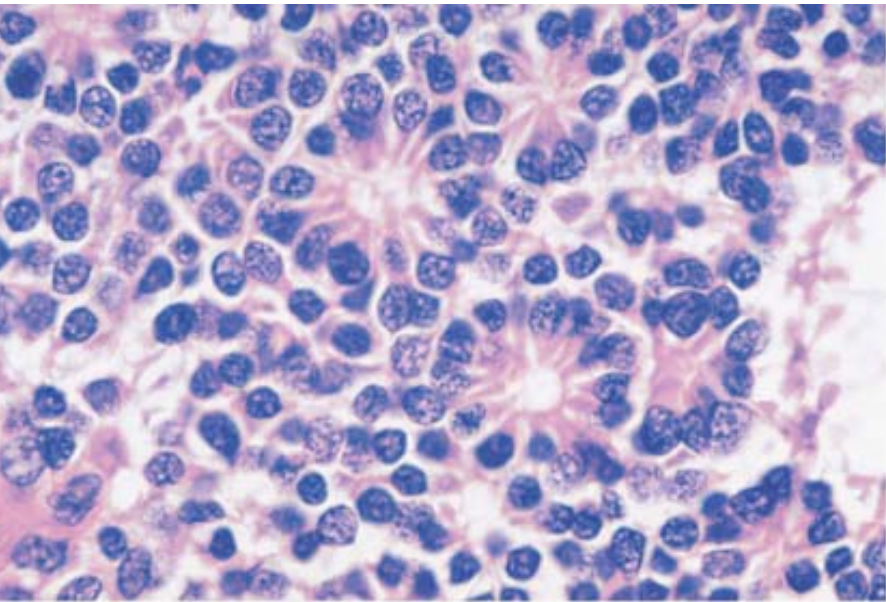


## ***Retinoblastom: große endophytische Tumoren mit Glaskörperaussaat***

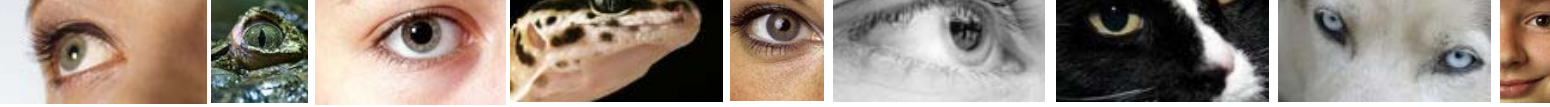




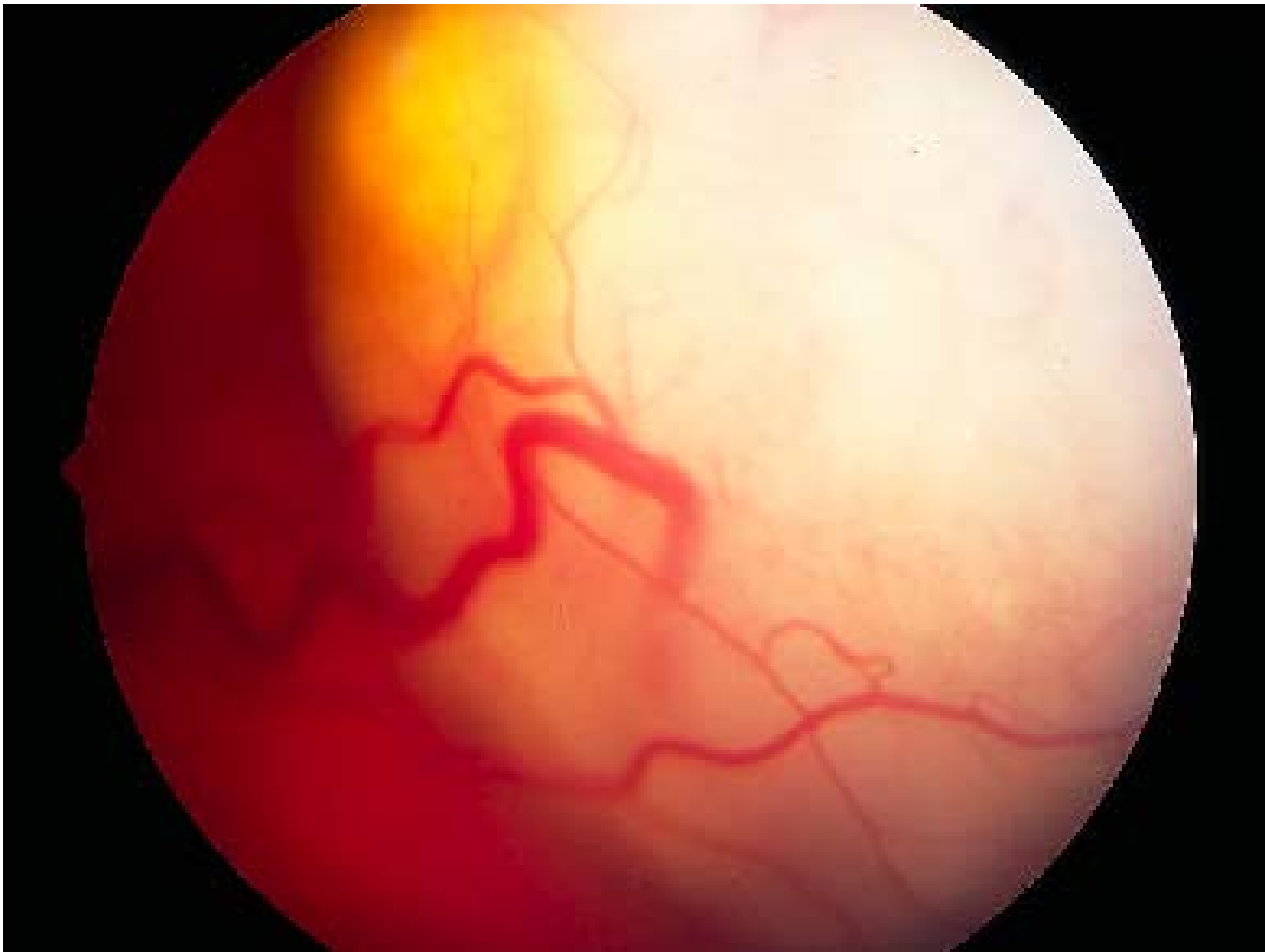## ***Retinoblastom: Histologie – Flexner Wintersteiner Rosetten***

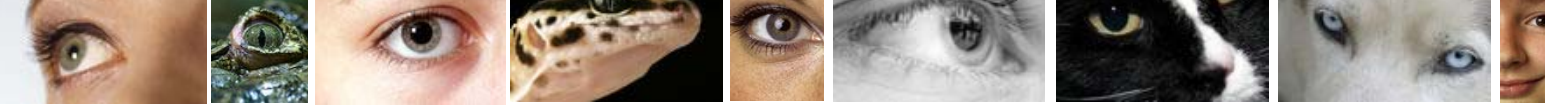


© 2005 Elsevier Ltd. Spalton et al: Atlas of Clinical Ophthalmology 3e



# ***Retinoblastom: 1:20.000 Geburten***





## ***Retinoblastom:***

genetisch bedingter Tumor: RB1 Gen

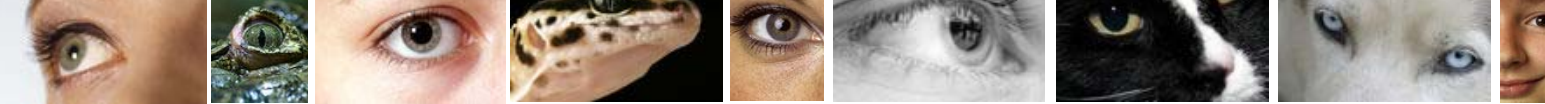
Sporadische Form, einseitig ca. 2/3 aller Retinoblastome

1/3 beidseitig und familiär gehäuft

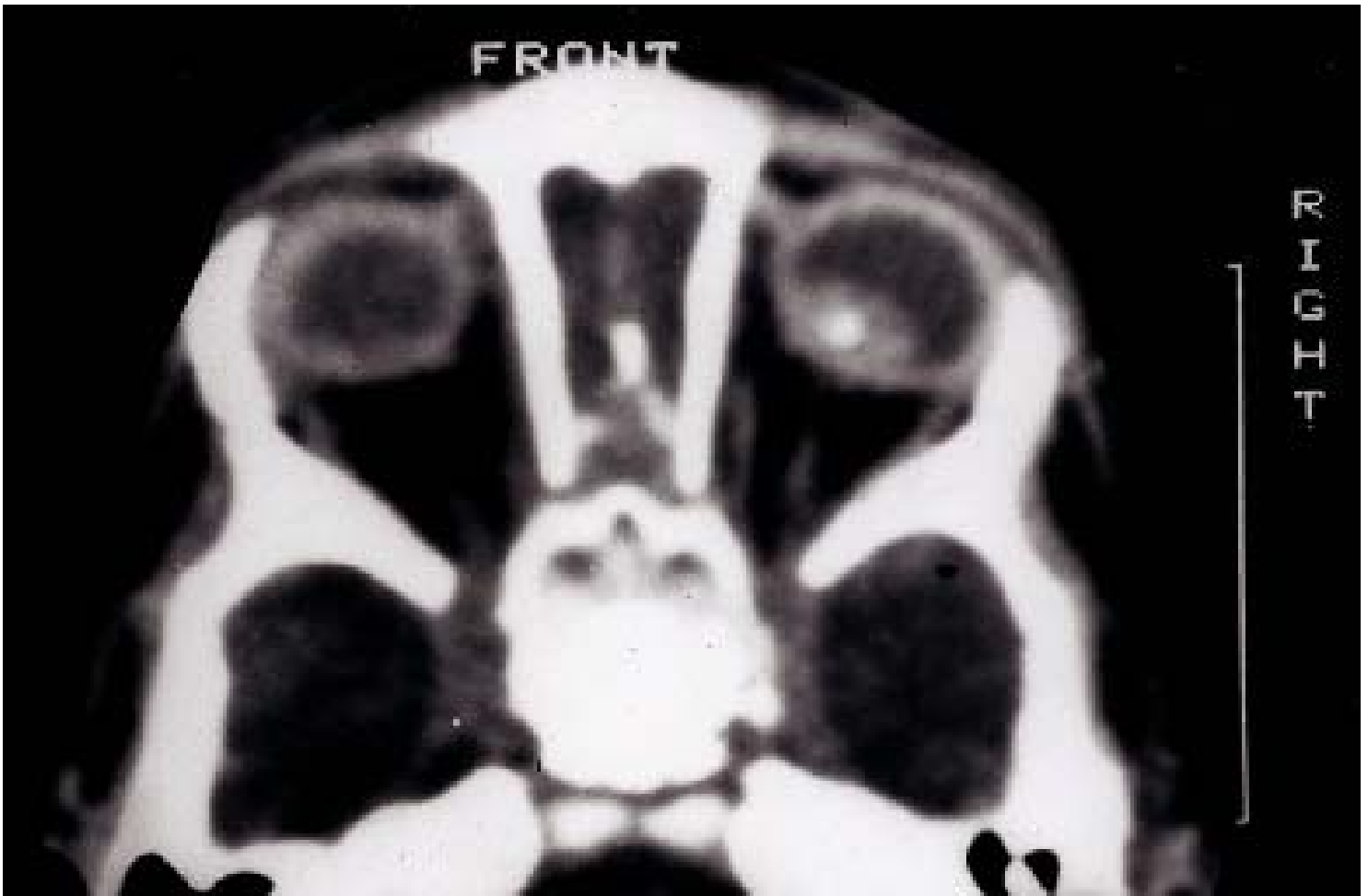
RB1 Gen liegt auf 13q14

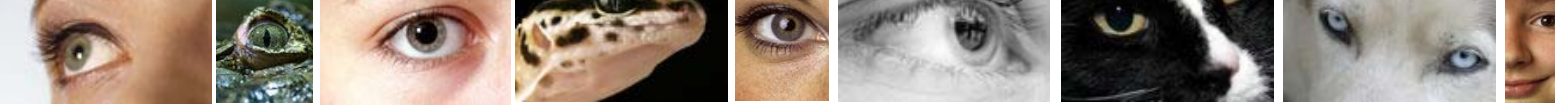
5 Jahresüberlebensrate = 95 %



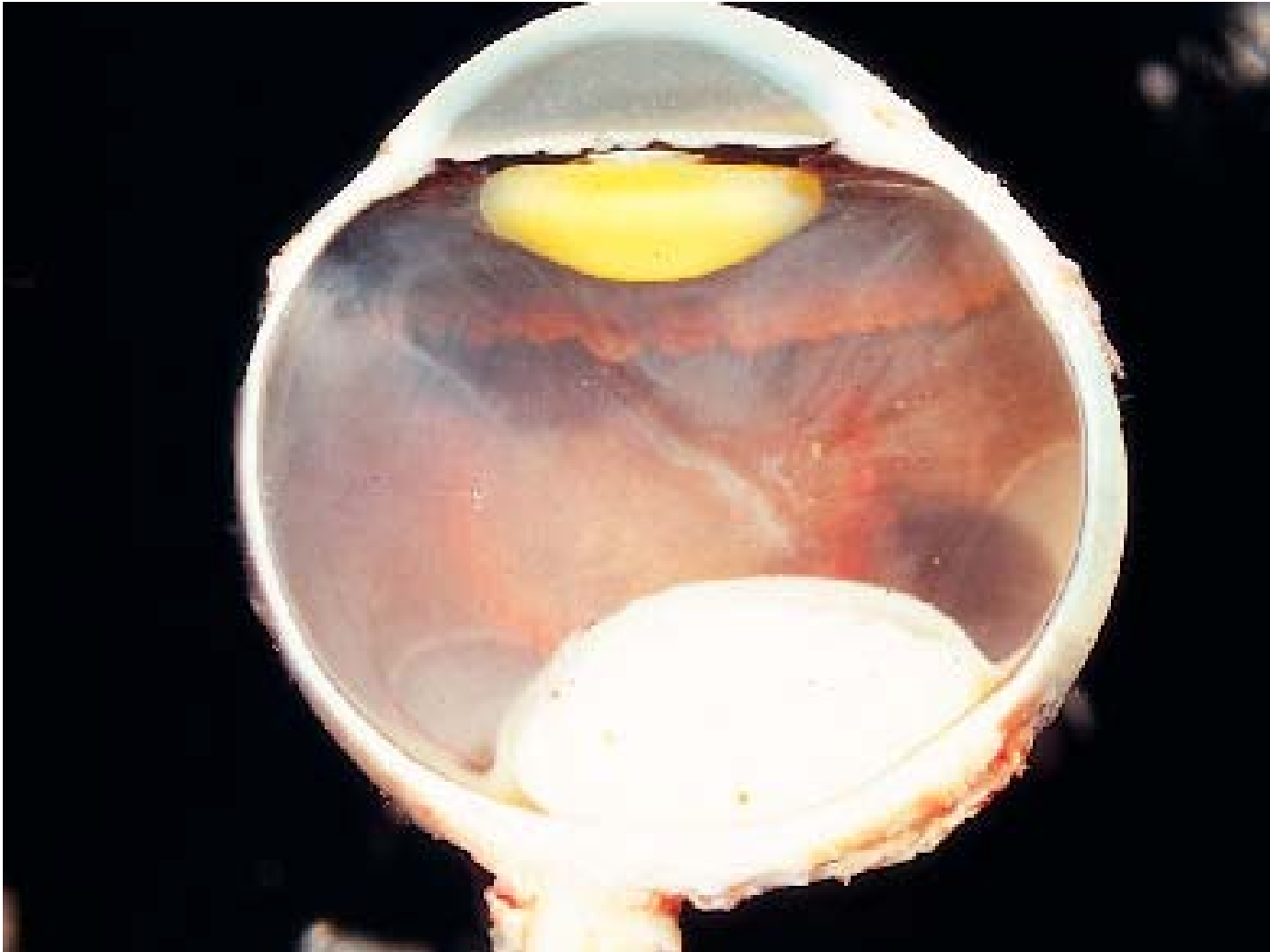


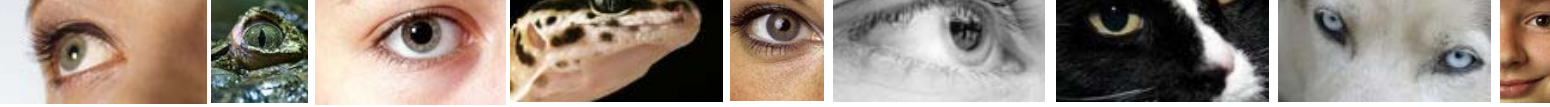
## *Retinoblastom: Verkalkungen im Tumor*





## *Retinoblastom*

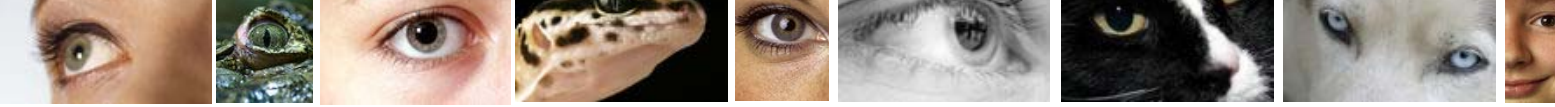




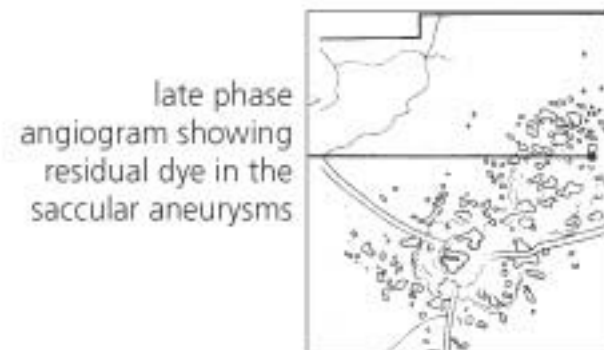
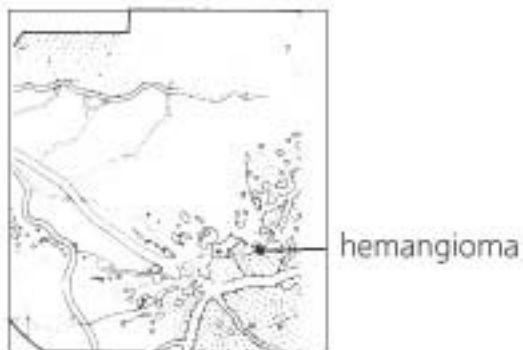
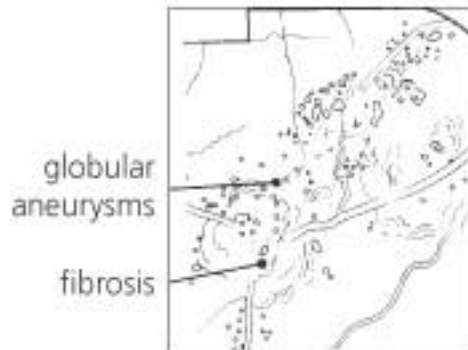
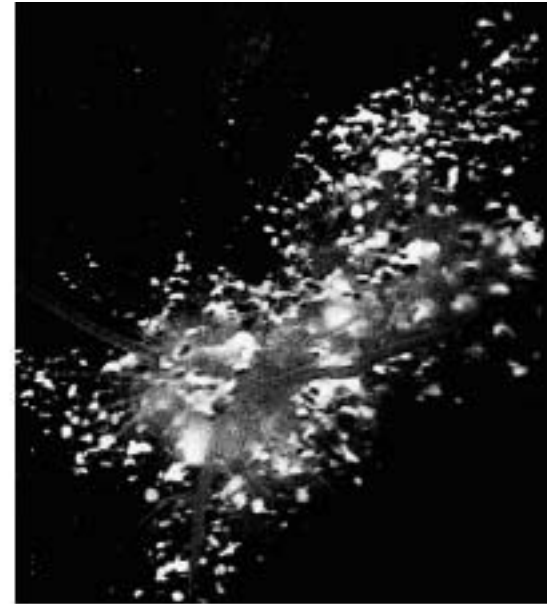
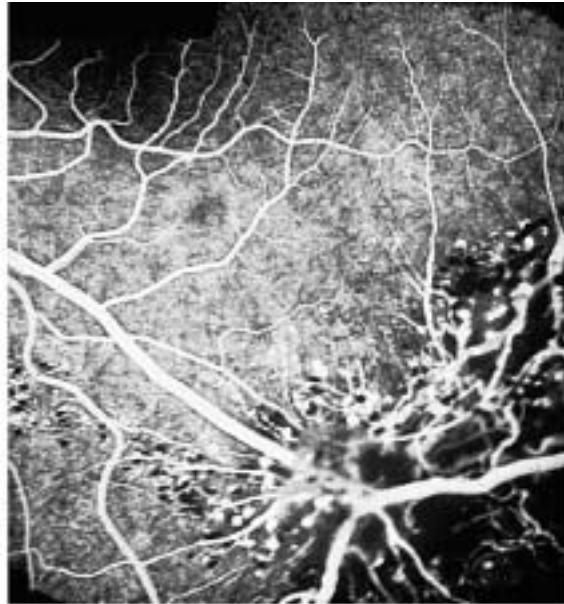
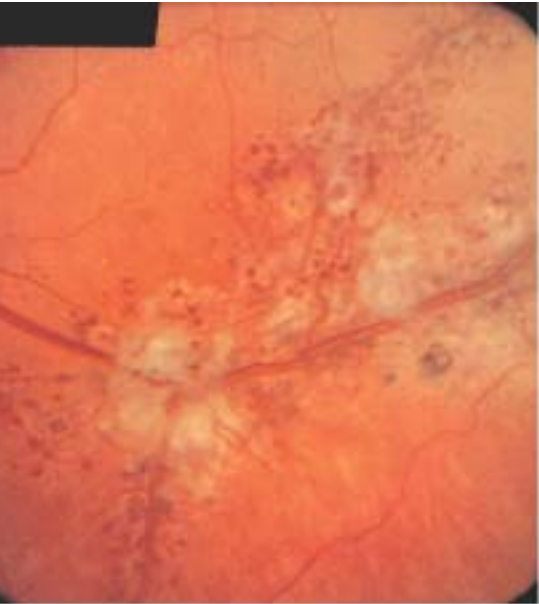
# Therapieoptionen Retinoblastom

- **Enukleation (erstes Auge)**
- **Brachytherapie (Plaque)**
- **Photokoagulation**
- **Kryotherapie**
- **Systemische Chemotherapie**

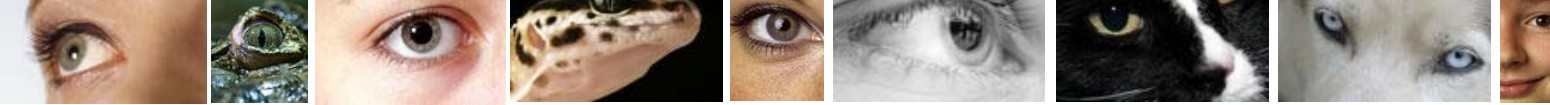
**Cave Teletherapie: Zweitmalignome**



## *Kavernöses Hämangiom*

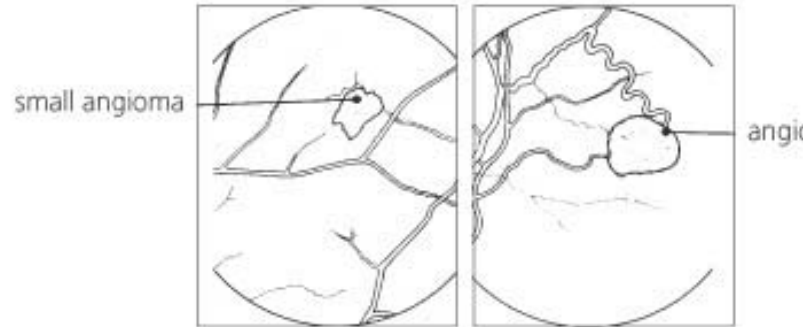
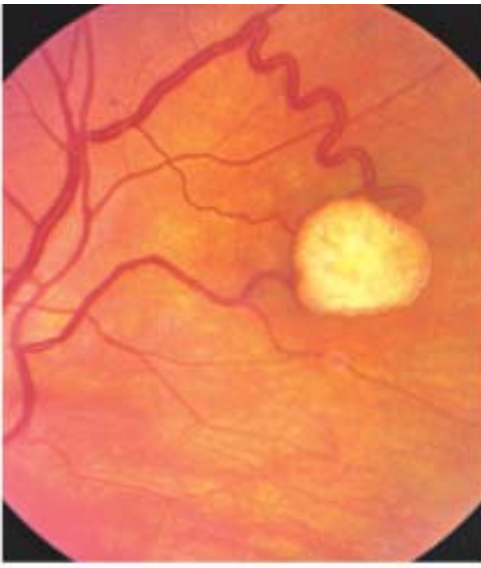
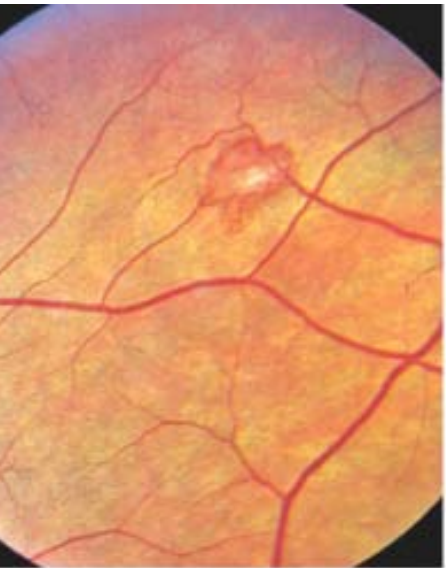
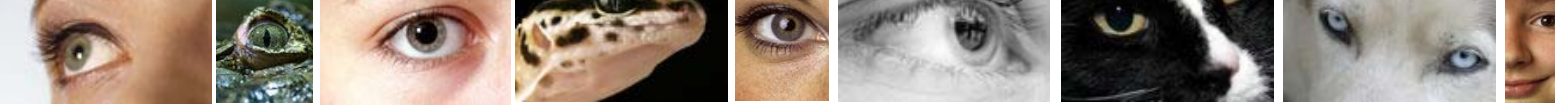




## ***Kapilläres Hämangiom***

### ***M. von Hippel Lindau***





# Kapilläres Hämangiom - M. von Hippel Lindau

